3. AUTOTRANSPLANTAČNÍ KONGRES

19.–21. KVĚTNA 2022
CUBEX, PRAHA, ČESKÁ REPUBLIKA

Finální program

3RD CONGRESS ON TOOTH TRANSPLANTATION

MAY 19–21, 2022
CUBEX, PRAGUE, CZECH REPUBLIC

Final Programme

ČESKÁ ORTODONTICKÁ SPOLEČNOST

ČSCHS
Česká stomatochirurgická společnost

ČESKÁ AKADEMIE DENTÁLNÍ ESTETIKY

UNIVERZITA KARLOVA

Czech Convention Bureau
CzechTourism

TRIOS 4 Wireless

3shape

Výkonný intraorální skener s funkcí detekce povrchových kazů, o 30 % delší životností baterií, možností bezdrátového provedení a okamžitého ohřevu pomocí chytrých koncovek.

- Realistické barevné skeny
- Rychlé a přesné skenování
- Bezdrátové i drátové provedení v jednom
- Možnost vlastní výroby

Speciální nabídka pouze pro účastníky kongresu

David Kodálík
produktový specialista CAD/CAM pro ordinace

+420 725 644 702
david.kodalik@dentamed.cz
dentamed.cz

Dentamed

Více informací u Vašeho obchodního zástupce nebo na **pristroje.dentamed.cz**

OBSAH

CONTENT

OBECNÉ INFORMACE

Místo konání
Cubex Centrum Praha
Na Strži 2097/63
140 00 Praha 4
Česká republika

Pořádající společnost

ČESKÁ ORTODONTICKÁ SPOLEČNOST

Kongres je podporován

ČESKÁ AKADEMIE DENTÁLNÍ ESTETIKY

ČSCHS
Česká stomatochirurgická společnost

Záštitu nad kongresem převzala

UNIVERZITA KARLOVA

Prezident
Dr. Ivo Marek, Ph.D.
E-mail: chairman@toothtransplantation.org

Vědecký sekretář
Ewa Czochrowska, DDS, Ph.D.
E-mail: scientific-secretary@toothtransplantation.org

Koordinátor programu
Dr. Josef Kučera, Ph.D.
E-mail: abstract@toothtransplantation.org

Koordinátor setkání pro stanovení protokolů transplantací zubů
Jan Streblov
E-mail: streblov@3dk.cz

Jednací jazyk
angličtina, čeština
(simultánní tlumočení)

Organizační sekretariát
GUARANT International spol. s r.o.
Jitka Puldová
Českomoravská 2510/19
190 00 Praha 9
Česká republika
Tel.: +420 284 001 444
E-mail: toothtransplantation@guarant.cz

Webové stránky kongresu
www.toothtransplantation.org

GENERAL INFORMATION

Congress Venue
Cubex Centre Prague
Na Strži 2097/63
140 00 Prague 4
Czech Republic

Organised by

ČESKÁ ORTODONTICKÁ SPOLEČNOST

Supported by

ČESKÁ AKADEMIE DENTÁLNÍ ESTETIKY

ČSCHS
Česká stomatochirurgická společnost

Under Patronage of

UNIVERZITA KARLOVA

Chairman
Dr. Ivo Marek, Ph.D.
Email: chairman@toothtransplantation.org

Scientific Secretary
Ewa Czochrowska, DDS, Ph.D.
E-mail: scientific-secretary@toothtransplantation.org

Program Coordinator
Dr. Josef Kučera, Ph.D.
E-mail: abstract@toothtransplantation.org

Coordinator of the Consensus Meeting on Tooth Transplantation
Dr. Jan Streblov
E-mail: streblov@3dk.cz

Congress Language
English, Czech
(simultaneous translation)

Organising Secretariat
GUARANT International spol. s r. o.
Jitka Puldová
Českomoravská 2510/19
190 00 Prague 9
Czech Republic
Tel: +420 284 001 444
E-mail: toothtransplantation@guarant.cz

Congress Website
www.toothtransplantation.org

ÚVODNÍ SLOVO

Milé kolegyně, milí kolegové,

jsou tomu už 4 roky, kdy Česká ortodontická společnost přijala nabídku zorganizovat 3. kongres autotransplantace zubů v Praze. Byla to pro nás velká čest, neboť takového privilegia se zatím dostalo jen zemím, které mají v současné době nejvýznamnější vliv na rozvoj autotransplantací zubů ve světě, jako je Polsko a Holandsko. Bohužel vše nešlo tak hladce jak jsme si představovali, či jak jsme si přáli, naopak, nepamatuji si, že by příprava některého z kongresů prošla tolika zatěžkávacími zkouškami, tolika komplikacemi. Dva měsíce před oficiálním termínem konání, kterým byl květen 2020, začala první světová vlna pandemie Covid 19, která znemožnila uskutečnění kongresu a termín byl následně 2x přesunut až na současné datum 19.–21. květen letošního roku. Když už vše vypadalo, že svět se dostává do normálních kolejí a epidemie po třech vlnách konečně zeslabuje, tak vypukla naprosto šílená, a pro nás do této doby nepřestavitelná, hrůzná válka na Ukrajině. A i když naše myšlenky byly spíše s trpícími lidmi v blízké zemi, byli jsme, na druhé straně, plně odpovědni za zdárný průběh kongresu, za jeho uskutečnění, a také za dobré jméno České ortodontické společnosti.

Nakonec 3. kongres autotransplantace zubů v Praze bude zatím největší akcí věnované autotransplantacím, která se kdy v historii konala. Je to z mnoha důvodů, ale jedním z nich je fakt, že nám přes všechny problémy potvrdili účast všichni hlavní přednášející, a to i po všech změnách termínů, které jim jistě značně zkomplikovaly život. A tak zde nebudou chybět nikdo ze špičkových odborníků zaobírajících se celoživotně autotransplantacemi zubu, jako jsou prof. L. Andersson, prof. O. Schwartz, Dr. Ewa Czochrowska, Dr. P. Plakwicz, celý Rotterdam team, ale i nevšední přednášející na tomto poli, jako je například Dr. Marco Rosa. Je nám nesmírnou ctí, že jedním z klíčových přednášejících bude profesor Mitsuhiro Tsukiboshi, který také povede celodenní kurz. Musíme dále poděkovat i všem sponzorům, kteří splnili své dřívější závazky a podpořili nás i nyní a bez nichž by nebylo možné kongres zorganizovat, a to především firmě Dentamed a Prodenta. A velký dík patří také všem Vám, kteří jste přijeli a dali jste naší práci smysl.

Organizační výbor, všichni jeho členové, s velkou podporou výboru ČOS a spřátelených odborných společností ČADE a ČSChS předvedli nesmírné úsilí, které, jak doufáme, povede k úspěšnému průběhu kongresu.

Vážené kolegyně a kolegové, je nám velkou ctí Vás přivítat v nádherné hlavním městě České republiky, v historické i moderní Praze, kde můžete strávit překrásný prodloužený víkend a užít si tento čas jak odborně, tak společensky.

S pozdravem a díky za celý organizační výbor

Ivo Marek
president kongresu

WELCOME MESSAGE

Dear Colleagues,

It is four years now since the Czech Orthodontic Society accepted the offer to organise the Third Congress on Tooth Transplantation in Prague. It was a great honour for us, because to date such a privilege has only been granted to countries that exert the greatest influence on the development of tooth autotransplantation internationally, such as Poland and the Netherlands. Unfortunately, things did not work as smoothly as we imagined or desired; on the contrary, I cannot remember the preparation of a congress ever being so thoroughly tested, or so complicated. Two months before the original official date of the congress (May 2020) the first wave of the Covid-19 worldwide pandemic started, preventing the event from taking place. The date was then moved twice, and the congress will now be held from 19th to 21st of May this year. When it finally looked as if the world was back on track and, after three waves the pandemic was receding, an absolutely insane, horrifying – and for us unimaginable – war broke out in Ukraine. And even if our thoughts were mostly preoccupied with the suffering of the people in the nearby country, we continued to be fully responsible for organising the congress, for its success, and for the good name of the Czech Orthodontic Society.

The Third Congress on Tooth Transplantation in Prague will be the largest event on autotransplantation ever held anywhere in the world. There are many reasons for this, including the fact that despite all the problems, all keynote speakers have re-confirmed their participation, even after the unexpected date changes have complicated their lives. We are delighted to welcome so many leading experts who have worked on tooth autotransplantation throughout their professional careers, including Professor Lars Andersson, Professor Ole Schwartz, Dr Ewa Czochrowska, Dr Paweł Plakwicz, and the entire Rotterdam team, as well as those who speak more rarely about this subject, such as Dr Marco Rosa. We are immensely honoured that our keynote speakers include Professor Mitsuhiro Tsukiboshi, who will also lead a whole-day course. We have to thank all our sponsors, who have honoured their earlier commitments and continue to support us; above all, the companies Dentamed and Prodenta. Without them, staging the congress would not be possible. A big thank you goes to all of you who attend the congress, as your presence gives our work meaning.

All members of the organising committee – with support from the committee of the Czech Orthodontic Society and allied professional societies, the Czech Academy of Dental Aesthetics and the Czech Society for Dentoalveolar Surgery – have put in a tremendous effort, which, we hope, will lead to a hugely successful congress.

Dear Colleagues, it is a great privilege to welcome you to the magnificent capital of the Czech Republic, the historical and modern Prague, where you can spend a fruitful long weekend and enjoy your time here both professionally and socially.

With greetings and thanks, on behalf of the organising committee,

Ivo Marek
President of the Congress

Nejste spokojeni se svým implantologickým systémem?

Zdarma nový za starý.

OSSTEM IMPLANT

HIOSSEN IMPLANT

MUDr. Kateřina Babičová
implantologie a augmentace

+420 725 644 701
katerina.babicova@dentamed.cz
dentamed.cz | **osstem.cz**

Dentamed

Více informací u Vašeho obchodního zástupce nebo na **osstem.cz**

ČASOVÝ ROZVRH / TIMETABLE

	19. 5. 2022	20. 5. 2022	21. 5. 2022	22. 5. 2022
	Kongresový kurz / Congress course	Hlavní vědecký program / Main scientific programme	Hlavní vědecký program / Main scientific programme	Consensus meeting
	Hall A3	Hall A1+A2	Hall A1+A2	Cubex centre
08:00	Registrace / Registration	Registrace / Registration	Registrace / Registration	
08:15				
08:30				
08:45				
09:00	M. Tsukiboshi Kongresový kurz / Congress course	Slavnostní zahájení / Opening ceremony	M. Rosa	Consensus meeting on tooth transplantation
09:15				
09:30		Ole Schwartz		
09:45			E. Czochrowska	
10:00		E. Czochrowska P. Plakwicz		
10:15			Radek Žižka	
10:30	Přestávka na kávu / Coffee break			
10:45				
11:00	M. Tsukiboshi Kongresový kurz / Congress course	Přestávka na kávu / Coffee break POSTER SECTION 1	Přestávka na kávu / Coffee break	
11:15				
11:30		M. Tsukiboshi	J. Streblov	
11:45				
12:00			K. K. Kaňovská D. Cunha A. Teramoto Ohara D. Nolte	
12:15				
12:30	Přestávka na oběd / Lunch break	E. Y. Suzuki B. Suzuki P. Promchaiwattana		
12:45				
13:00		Přestávka na oběd / Lunch break	Přestávka na oběd / Lunch break	
13:15				
13:30	M. Tsukiboshi Kongresový kurz / Congress course			
13:45				
14:00		Rotterdam team: D. Barendregt M. Leunisse M. Linsen E. Eggink	E. Eggink D. Barendregt	
14:15				
14:30			M. Daian F. Nunes	
14:45				
15:00	Přestávka na kávu / Coffee break		L. Andersson	
15:15				
15:30	M. Tsukiboshi Kongresový kurz / Congress course	Přestávka na kávu / Coffee break POSTER SECTION 2	Přestávka na kávu / Coffee break	
15:45				
16:00		M. EzEldeen J. Waytt M. Starosta	S. Barber	
16:15				
16:30			Y. Matsuzawa M. Novosad L. Gregor P. Plackwicz	
16:45		I. Marek		
17:00				
17:15				
17:30			Závěr kongresu / Closing ceremony	
17:45				
20:00 – 24:00		Presidentský večer / President's reception		

KONGRESOVÝ KURZ / CONGRESS COURSE
ČTVRTEK 19. KVĚTNA 2022 / THURSDAY, MAY 19, 2022

08:00–09:00	**Registrace / Registration**
09:00–10:30	**Mitsuhiro Tsukiboshi:** Autotransplantation of teeth
10:30–11:00	Přestávka na kávu / Coffee break
11:00–12:30	**Mitsuhiro Tsukiboshi:** Autotransplantation of teeth
12:30–13:30	Oběd / Lunch
13:30–15:00	**Mitsuhiro Tsukiboshi:** Autotransplantation of teeth
15:00–15:30	Přestávka na kávu / Coffee break
15:30–17:00	**Mitsuhiro Tsukiboshi:** Autotransplantation of teeth

HLAVNÍ ODBORNÝ PROGRAM – DEN 1 / MAIN SCIENTIFIC PROGRAMME – DAY 1
PÁTEK 20. KVĚTNA 2022 / FRIDAY, MAY 20, 2022

Předsedající / Chairpersons: Sophy Barber, Jan Streblov	
09:00–09:30	**Zahajovací ceremoniál – cimbálová muzika Grajcar / Opening ceremony – dulcimer music Grajcar** **Lars Andersson:** Jens Andreasen memorial lecture
09:30–10:00	**Ole Schwartz:** Long-term prognosis of autotransplanted teeth
10:00–10:55	**Pawel Plakwicz, Ewa Czochrowska:** Protocol for autotranplantation of developing teeth
10:55–11:00	Diskuze / Discussion
11:00–11:30	Přestávka na kávu / Coffee break, POSTER SECTION 1
Předsedající / Chairpersons: Dick Barendregt, Jiří Krug	
11:30–12:15	**Mitsuhiro Tsukiboshi:** Life-long journey with autotransplantation of teeth
12:15–12:20	Diskuze / Discussion
12:20–12:30	**Eduardo Yugo Suzuki:** Tooth transplantation tenting graft method for alveolar ridge augmentation: innovative technique and case series
12:30–12:40	**Boonsiva Suzuki:** Smart springs: a simple method to upright impacted mandibular third molars
12:40–12:50	**Pattarin Promchaiwattana:** Enhanced periodontal ligament following orthodontic tooth movement
12:50–12:55	Diskuze / Discussion
13:00–14:00	Oběd / Lunch
Předsedající / Chairpersons: Ewa Czochrowska, Martin Starosta	
14:00–15:25	**Rotterdam team – Dick Barendregt, Manfred Leunisse, Marcel Linsen, Edwin Eggink:** Clinical proof of bone formation by autotransplants and out of the box solutions for replacing anterior missing teeth
15:25–15:30	Diskuze / Discussion
15:30–16:00	Přestávka na kávu / Coffee break, POSTER SECTION 2
Předsedající / Chairpersons: Manfred Leunisse, Ladislav Gregor	
16:00–16:10	**Mostafa Ezeldeen:** The use of CBCT guidance for tooth transplantation in children – Part I: 3D planning in the arteficial intelligence era, 3D printing and 3D patterns of healing
16:10–16:20	**Jan Wyatt:** The use of CBCT guidance for tooth transplantation in children – Part II: Surgical technique, follow-up, short and long-term treatment outcome
16:20–16:30	**Martin Starosta:** History of tooth tranplantation in Czech Republic
16:30–16:35	Diskuze / Discussion
16:35–17:05	**Ivo Marek:** The current view of autotranplantation: what are the right indications?
17:05–17:10	Diskuze / Discussion
17:10–17:15	**Udělení čestného členství / Honorary membership award**
20:00–24:00	**Prezidentský večer / President's reception**

HLAVNÍ ODBORNÝ PROGRAM – DEN 2 / MAIN SCIENTIFIC PROGRAMME – DAY 2

SOBOTA 21. KVĚTNA 2022 / SATURDAY, MAY 21, 2022

Moderátor / Moderator: Martin Tomeček	
09:00–09:15	**Představení kazuistiky – vstupní data / Case presentation – initial records**
09:15–09:40	**Marco Rosa:** Upper missing teeth incisors: space closure for excellence in all malocclusions
09:40–10:05	**Ewa Czochrowska:** Autotranplantation of developing premolars to replace missing maxillary central incisors
10:05–10:30	**Radek Žižka:** Endodontic treatment of complicated teeth – where is the limit?
10:30–10:45	Diskuze / Discussion
10:45–11:00	**Představení kazuistiky – výsledky / Case presentation – results**
11:00–11:30	Přestávka na kávu / Coffee break
Předsedající / Chairpersons: Lars Andersson, Pawel Plakwicz	
11:30–11:55	**Jan Streblov:** Reshaping of premolars transplanted to the anterior maxilla
11:55–12:00	Discussion / Diskuze
12:00–12:10	**Karin Klimo Kaňovská:** Autotransplantations of impacted teeth, indications and treatment limits
12:10–12:20	**Deise Cunha:** Use of computer-aided planning and rapid prototyping in autotransplantation of teeth in children
12:20–12:30	**Alberto Teramoto Ohara:** Adamantine tissue autograft: an alternative rehabilitation treatment for tooth transplantation
12:30–12:50	**Dirk Nolte:** Primary tooth autotransplantation: Looking back on 15 years of clinical practice
12:50–12:55	Diskuze / Discussion
13:00–14:00	Oběd / Lunch
Předsedající / Chairpersons: Eva Šrámková, Radek Žižka	
14:00–14:25	**Edwin Eggink and Dick Barendregt:** Prevention, diagnosis and treatment of endodontic complications after autotransplantation
14:25–14:35	**Manuela Daian:** Autotransplantation and complications: case presentations
14:35–14:45	**Fernanda Nunes:** Success criteria and methods for evaluating the success of autotransplanted teeth
14:45–15:15	**Lars Andersson:** How to understand and manage ankylosis after autotransplantation of teeth in growing patients
15:15–15:20	Diskuze / Discussion
15:20–15:50	Přestávka na kávu / Coffee break
Předsedající / Chairpersons: Ivo Marek, Josef Kučera	
15:50–16:15	**Sophie Barber:** Examination of the evidence base for tooth autotransplantation
16:15–16:20	Diskuze / Discussion
16:20–16:30	**Yusuke Matsuzawa:** A clinical research of surgical uprighting for impacted lower second molar
16:30–16:40	**Michal Novosad:** Autostransplantation into the atrophied alveolar proces of the distal segment of the mandible
16:40–16:50	**Ladislav Gregor:** Intra-alveolar transplantation: surgical extrusion
16:50–17:15	**Pawel Plakwicz:** Trans-alveolar autotransplantation of ectopic teeth
17:15–17:20	Diskuze / Discussion

POKYNY PRO ŘEČNÍKY (AUTORY)

Jak předložit prezentaci na kongresu

Všechny digitální soubory potřebné pro prezentaci odevzdejte v místnosti **Přípravna pro řečníky.** Techničtí specialisté vám pomohou nahrát všechny soubory, abyste měli vše připraveno před každým prezentováním.

Přijďte prosím do **přípravny pro řečníky** alespoň 1,5 hodiny před začátkem svého vystoupení. V případě, že je vaše vystoupení naplánováno na dopolední část, přijďte do přípravny pro řečníky den před začátkem prezentace. Přípravna pro řečníky se nachází **v salonku D**.

Otevírací doba místnosti přípravny pro řečníky

Čtvrtek 19. května	14:00–17:00
Pátek 20. května	08:00–17:30
Sobota 21. května	08:00–17:30

Abyste se vyhnuli případným problémům s prezentací, ujistěte se, zda splňuje potřebné požadavky, a pozorně si přečtěte níže uvedené pokyny.

Jak připravit prezentaci

Pokyny pro aplikaci PowerPoint

- Použijte program Microsoft PowerPoint 2003 nebo vyšší (*.ppt) nebo (*pptx), abyste zaručili, že budou správně fungovat na počítači na místě.
- Připravte si prezentaci ve formátu **16:9**. Doporučujeme vám uložit prezentaci v aplikaci PowerPoint ve formátu PPTX namísto PPS.
- Pokud máte v prezentaci obrázky nebo videa, vložte je do souboru prezentace, nepoužívejte odkazy.
- Mějte prosím na paměti, že organizátor nemůže zaručit kvalitu prezentací na počítačích Macintosh, a proto si předem (3 hodiny před začátkem sezení) ověřte jejich kompatibilitu se systémem Windows.
- Prezentační systém používaný během kongresu podporuje také prezentace ve formátu PDF.

Písma

K dispozici jsou pouze písma obsažená v základní instalaci MS-Windows (anglická verze Windows). Použití jiných písem, která nejsou součástí systému Windows, může způsobit nesprávné rozložení / styl prezentace. Doporučená písma jsou: Arial, Times New Roman, Tahoma a Calibri. Pokud trváte na použití jiných písem, je třeba je do prezentace vložit výběrem správné možnosti při ukládání prezentace, viz podrobnosti níže:

- Klikněte na „Soubor" a poté na „Uložit jako".
- V nabídce „Nástroje" vyberte možnost „Vložit písma True Type".

Jak uložit a odeslat prezentaci

Jak uložit prezentaci

Uložte prezentaci na jeden z následujících disků nebo médií:

- USB flash disk
- Externí pevný nebo SSD disk

Uložení všech souborů souvisejících s prezentací (soubor aplikace PowerPoint, filmové soubory / video atd.) do jedné složky / umístění. V případě, že během kongresu prezentujete více než jednu prezentaci, uložte různé prezentace do různých složek a jasně je pojmenujte, abyste předešli nedorozuměním a problémům na místě. Vždy si vytvořte záložní kopii prezentace a uložte ji na jiný přenosný disk nebo médium než původní prezentaci. Disky DVD-RAM a Blu-ray nebudou akceptovány.

Další informace

Vlastní počítač pro prezentaci bude akceptován **pouze v naléhavých případech,** pokud používáte McIntosh, dostavte se do přípravny pro řečníky 3 hodiny před prezentací.

Žádáme všechny řečníky, aby dodržovali čas svého vystoupení.

Standardní vybavení zasedacích místností

Níže naleznete seznam standardního vybavení:

- Datový videoprojektor
- Obrazovka
- Laptop
- Zvukový systém
- Mikrofony
- Dálkové ovládání s laserovým ukazovátkem

INSTRUCTIONS FOR SPEAKERS (AUTHORS)

How to submit presentation at the congress

Please submit all digital files needed for your presentation in the **Speakers' Ready Room.** Technical specialists will help you to upload all files so everything is ready before each session.

Please come to the **Speakers' Ready Room** at least 1,5 hours before the beginning of your session. In case your speech has been scheduled for morning session come to the Speakers' Ready Room the day before your presentation. Speakers' Ready Room is located **in the meeting room D**.

Speakers' Ready Room opening hours

Thursday, May 19	14:00–17:00
Friday, May 20	08:00–17:30
Saturday, May 21	08:00–17:30

In order to avoid any problems with your presentation, please make sure whether it meets the necessary needs and read carefully the instructions below.

How to prepare presentation

PowerPoint instructions

- Use the Microsoft PowerPoint 2003 or higher (*.ppt) or (*pptx) to guarantee they will work properly on an on-site PC.
- Prepare presentation in **16:9**. We recommend you to save your PowerPoint presentation using PPTX format instead of PPS.
- If you have pictures or videos in the presentation, please insert them in the presentation file, do not use links.
- Please keep on mind that organizer cannot guarantee the quality of Macintosh-based presentations; so check in advance (3 hours before your session starts) their Windows compatibility.
- Note that the presentation system used during the congress also supports the PDF presentations.

Fonts

Only fonts included in the basic installation of MS-Windows are available (English version of Windows). Use of other fonts not included in Windows can cause the wrong layout / style of the presentation. Suggested fonts are: Arial, Times New Roman, Tahoma, and Calibri. If you insist on using different fonts, these must be embedded into the presentation by choosing the right option when saving the presentation, see details below:

- Click on „File", then „Save As"
- Check the „Tools" menu and select „Embed True Type Fonts"

How to save and submit presentation

How to save presentation

Save your presentation in one of the following disc or medium:

- USB flash drive
- External hard or solid state drive

Save all files associated with the presentation (PowerPoint file, movie / video files, etc.) to one folder / location. In case you are presenting more than one presentation during the congress, save different presentations to different folders and name them clearly to avoid on-site misunderstandings and problems. Always make a backup copy of your presentation and save it on a different portable disc or medium than the original presentation. DVD-RAM and Blu-ray Disc will not be available.

Other information

Your own computer for the presentation will be accepted **only in urgent cases**, if you use McIntosh, please come to Speakers' Ready Room 3 hours before your presentation.

All speakers are requested to keep the time of their presentation.

Standard equipment of the session rooms

See below the list of standard equipment:

- Data video projector
- Screen
- Laptop
- Sound system
- Microphones
- Remote control with laser pointer

HLAVNÍ PŘEDNÁŠEJÍCÍ / KEYNOTE SPEAKERS

Mitsuhiro Tsukiboshi, DDS, PhD

Ole Schwartz, DDS, PhD




Rotterdam team:
Dr. Dick Steven Barendregt DDS, MSc, PhD,
Manfred Leunisse, Marcel Linsen,
Edwin Eggink

Dr. Ivo Marek, Ph.D.


Ewa Czochrowska, DDS, PhD,
Paweł Plakwicz, PhD, DDS, MFDSRCS

Dr. Marco Rosa, M.D., D.D.S., D.Orthod.

MDDr. Radovan Žižka, Ph.D.

MUDr. Jan Streblov

Lars Andersson DDS, PhD, DrOdont

Dr. Sophy Barber, BDS, MSc, MOrth RSC(Ed), PhD

KNIHA ABSTRAKTŮ / BOOK OF ABSTRACTS

KEYNOTE LECTURES

Congress course
Čtvrtek 19. května 2022 / Thursday, May 19, 2022
09:00–17:00

Autotransplantation of teeth

Mitsuhiro Tsukiboshi

Complex treatment plans in implant often include situations where the choices of autotransplantation of teeth (ATT) have been overlooked. If recipient sites are jeopardized for placing implants, more time, cost and techniques are required. However, if there is a good candidate as a donor tooth found in the same mouth, transplantation can be the more appropriate option than implant. For example, the case where sinus lifting or ridge augmentation is indicated can be preferable and advantageous for ATT. If patients are younger than twenty, implant is hardly indicated. There are two more families of ATT; intentional replantation and surgical extrusion, in which the wound healing mechanism is almost same. Jeopardized teeth, themselves may be able to be preserved with those techniques. In my presentation, the advantages, wound healing, techniques, indications and prognosis will be discussed. The lecture will be extensively illustrated with many clinical cases of ATT, intentional replantation and surgical extrusion.

Learning objects:
participants should be able to:
- Understand Advantages of ATT over implants
- Learn the wound healing in ATT
- Learn the techniques of ATT for success
- Recognize clinical situations suitable for ATT, intentional replantation and surgical extrusion
- Evaluate the prognosis of ATT

Keynote 1
Pátek 20. května 2022 / Friday, May 20, 2022
09:30–10:00

Long-term survival and prognosis of autotransplanted teeth

Ole Schwartz

The optimal criterias of a successful autotransplanted tooth includes: alveolar growth and eruption in synchrony with neighbouring teeth, and the capacity of the soft tissue of the donor tooth to induce normal periodontal ligament, obliteration of the pulp, and further root formation, formation of new alveolar bone and gingiva at the recipient site, including the capacity of the grafted tooth to be moved with orthodontic forces.

During the last 30 years, a number of long-term studies of autotransplantation of teeth, including **Meta-analysis** and **Life-table analysis** of several large controlled data materials (more than 4000 transplantations, followed from 3 to 47 years) have revealed a series of relevant prognostic factors of various significance on the long term "survival". With the limitations such comparison of different data materials demand, some of the factors with potentially significant impact on long-term survival will be presented, including: Root development of the graft, tooth type, endodontic treatment, splinting, antibiotics, experience of the surgeon, in private practice vs. in university clinics, pre- and postoperative orthodontic treatment, postoperative prosthodontic treatment, and other factors of relevance to the long term satisfactory survival and function of transplanted teeth.

Even cryopreserved teeth can be autotransplanted, with documented function and normal pulp and periodontal ligament similar to fresh grafts for more than 30 years after autotransplantation, with initial cryopreservation of the tooth graft for 5 years.

Complications like ankylosis, necrosis of the obliterated pulp and invasive cervical resorption has been demonstrated to appear many years after tooth transplantation. It is possible to treat obliterated pulp with endodontics, however ankylosis and invasive root resorption will eventually lead to loss of the grafted tooth.

Autotransplantation of teeth present a long-term survival, function and aestetically satisfactory results after more than 20–40 years, comparable to – and in some aspects superior to – dental implants. However, transplantation of premolars to the incisor maxillary region may compose a major challenge to the transplantation team, including orthodontist, surgeon and prostodontist, achieving predictable long lasting pleasing aestetic results to the patients. Such resent long-term results will be presented from Copenhagen, and related to previous publications.

Keynote 2
Pátek 20. května 2022 / Friday, May 20, 2022
10:00–10:55

Protocol for autotransplantation of developing teeth

Pawel Plakwicz, Ewa Monika Czochrowska

Autotransplantation of teeth before the root is fully formed is an established treatment option for replacing missing teeth in growing individuals. Favorable orthodontic indications, good surgical access and optimal match between the donor tooth and the recipient site are prerequisites for a successful outcome. Premolars with developing roots due to their morphology and position in the dental arch are optimal donors with success reported over 90 per cent. The protocol for transplantation of developing teeth was established at the University in Oslo more than four decades ago and has been successfully applied in Poland since 2000.

The key elements described in the protocol for autotransplantation of developing teeth include:

- description of the best stages of root development in relation to the alveolar bone morphology at the recipient site and presentation of existing scientific evidence,
- surgical planning regarding the morphology of the donor and recipient site with the use of CBCT in treatment planning,
- pre-surgical orthodontic treatment,
- description of the surgical technique in main orthodontic indications,
- follow-up with a description of signs of success and failure,
- post-surgical orthodontic treatment in relation to the root development of the transplant

---

Keynote 3
Pátek 20. května 2022 / Friday, May 20, 2022
11:30–12:15

Life-Long Journey with Autotransplantation of teeth

Mitsuhiro Tsukiboshi

Autotransplantation of teeth has been performed for centuries, but its popularity has varied over the years due to unpredictable results. However, with recent advancements in technology and better biological understanding, ATT has become more predictable. Yet, many clinicians are still not confident about this technique, in part due to the lack of studies on the long-term outcomes of these cases.

I have performed more than 1,000 ATT since 1987 in general private practice. Almost all of the cases were carefully recorded with photographs and radiographs in a standardized manner and many were followed long-term. In my presentation, I would like to discuss the advantages of ATT with sharing the life-long experience of mine.

Keynote 4
Pátek 20. května 2022 / Friday, May 20, 2022
14:00–15:25

Clinical proof of bone formation by autotransplants and out of the box solutions for replacing anterior missing teeth

Dick Barendregt, Marcel Linssen, Manfred Leunisse, Edwin Eggink

Transplantation of premolars to the region of missing central incisors is a procedure enabling an esthetic recovery of both pink and white esthetics and provides a solution which doesn't interfere with the normal development of the dento-alveolar complex.

For replacing a unilateral incisor, transplantation of a premolar often results in a less favorable outcome because the dimension of a premolar normally doesn't match with the dimension of the smaller lateral incisor. In this lecture we will present different treatment options such as transplantation of a lower central incisor to the region of an upper lateral incisor. You will learn how to determine a tooth size discrepancy caused by reduced dimension of the upper laterals, its implications, the solutions and opportunities caused by this orthodontic deviation.

After trauma to the anterior region with loss of teeth, the alveolar bone is also compromised. Transplantation of teeth into this defect followed by orthodontic extrusion will resolve this defect. In this lecture we will show you the potential of the periodontal ligament in inducing bone growth in cases where there is no bone present.

In this lecture most of the cases shown will be transplantations of fully developed teeth. We will show you the procedure followed by our team to do these transplantations in a predictable way.

Keynote 5
Pátek 20. května 2022 / Friday, May 20, 2022
16:45–17:15

The current view of autotransplantation; what are the right indications?

Ivo Marek[1,2], Martin Starosta[3,4], Michal Novosad.[2], Radek Žižka[1,5]
[1]The Department of Orthodontics, University of Palacký, Olomouc, Czech Republic; [2]Dental Clinic STOMMA, Břeclav, Czech Republic; [3]Collegium Dentalis s.r.o., Olomouc, Czech Republic; [4]First Medical Faculty, Charles University, Praha, Czech Republic; [5] Dentalis, Skalka nad Vahom, Slovakia

In recent years, teeth autotransplantation has developed very rapidly, in a way that is not typical of other surgical procedures in dental surgery. This is largely thanks to the shift in indications: autotransplantation has been extended from the immature teeth as the erstwhile sole indication to mature teeth as well. This has massively broadened the indications, because any tooth that is planned to be extracted in an adult patient for orthodontic reasons can be autotransplanted in the same individual to a site where a tooth is missing – a situation that would otherwise be resolved using an implant. This way of thinking is entirely revolutionary and we might well ask whether the procedure should be accepted as a legitimate medical method or not. In order for it to qualify as such, we need to have evidence-based medical data: are the autotransplantations of teeth whose development is complete as successful as those of teeth whose development is incomplete? Those data are already available. But should the frequent ankylosis of mature teeth be considered as a failure and a complication, or not? In some cases, external replacement resorption leads to complete root resorption, subsequent loss of the tooth and hence to the failure of the autotransplantation. Fortunately, in the majority of cases this clinical situation does not occur and the autotransplanted teeth has a favourable long-term prognosis. How can we prevent the ankylosis, and how serious clinical finding is it?

Keynote 6
Sobota 21. května 2022 / Saturday, May 21, 2022
09:15–09:40

Upper missing teeth incisors: Space closure looking for excellence in all malocclusions

Marco Rosa
Angle Society of Europe

In case of missing incisors, space closure could be an effective alternative. This solution is nowadays not only possible in all malocclusions, but also is an evidence based treatment.

Orthodontic space closure is the first step of an interdisciplinary treatment, which leads to long term health, aesthetic and function.

Conversely, this treatment is sometimes difficult and challenging: even more when the gingival margins are visible and in case of periodontal breakdown. The lecture will outline and discuss the rationale, the priorities and some crucial details in the clinical method.

Participants will learn:
- guidelines of the interdisciplinary (ortho/perio/prosthod) treatment of missing teeth in the smile area.
- How to close the spaces in all malocclusions.
- Crucial detail of orthodontic finishing.

Keynote 7
Sobota 21. května 2022 / Saturday, May 21, 2022
09:40–10:05

Autotransplanation of developing premolars to replace missing maxillary central incisors

Ewa Czochrowska
Department of Orthodontics, Medical University in Warsaw, Poland

Traumatic loss of upper incisors in growing patients is the most important indication for the autotransplanation of teeth. Successful transplants not only provide a life-long tooth replacement but can also preserve the alveolar bone and promote bone regeneration in traumatised alveolar processes. However, tooth transplantation is a technique sensitive procedure and requires careful diagnosis and case selection, a good understanding of relevant tooth transplantation biological principles and careful execution of the optimal surgical and follow-up protocols. Developing premolars were documented to be the optimal donors with excellent long-term survival and success. However, if transplanted to anterior maxilla, their morphology clearly differs from the incisor's morphology and subsequent reshaping using composite resins or porcelain veneers is needed for a satisfactory smile esthetics. In this case presentation the benefits and difficulties of this technique when applied to treat the traumatic loss of maxillary incisors will be discussed and summarized.

Keynote 8
Sobota 21. května 2022 / Saturday, May 21, 2022
10:05–10:30

Endodontic treatment of complicated teeth – where is the limit?

Radovan Žižka[1], Jiří Šedý[2]
[1]Department of Dentistry, Faculty of Medicine and Dentistry, Palacky University, Olomouc, Czech Republic; [2]Department of Anatomy, Faculty of Medicine and Dentistry, Palacky University, Olomouc, Czech Republic

In our clinical practice we can encounter teeth with complex anatomy, development anomalies or wide open apices which can be challenging for endodontic treatment. Very often the extraction is considered and indicated for such cases due to low succes rate of the conventional root canal treatment. But in developing individuals, this treatment can lead to insufficient development of jaw and subsequent deficiency of bone volume. Moreover, this outcome can be disadventageous for further reconstruction. The authors present different cases of endodontic treatment (non-surgical, surgical or combined) which lead to preservation of teeth in a predictable way.

Keynote 9
Sobota 21. května 2022 / Saturday, May 21, 2022
11:30–11:55

Restoring an autotransplanted premolar in the place of a central incisor

Jan Streblov

Most of the literature on tooth autotransplantation quite rightly focuses on biologic proceses and surgical techniques to achieve the desired outcome – a successfull healing and further growth of a transplanted tooth. However, less attention has been focused on the restorative procedures with the aim of mimicking the colour and shape of a completely different tooth. From the esthetic point of view central incisor is undoubtedly the most important tooth in a pleasing smile. To attain the highest goal of minimally invasive, long lasting restoration in a growing teenager, several rules have to be followed and surgical, biologic, restorative and orthodontic aspects need to be considered to achieve the desired outcome. The lecture will deal with the above mentioned aspects and illustrate the key points leading to a successfull transformation of a premolar into a central incisor.

Keynote 10
Sobota 21. května 2022 / Saturday, May 21, 2022
14:00–14:25

Prevention, diagnosis and treatment of endodontic complications after autotransplantation

Edwin Eggink and Dick Barendregt

Transplantation of premolars to the region of missing central incisors is a procedure enabling an esthetic recovery of both pink and white esthetics and provides a solution which doesn't interfere with the normal development of the dento-alveolar complex. Whether this is done with complete or incomplete root formation, in both cases there is a chance endodontic complications will occur. This can be in an early stage as well as years after the transplantation. In this lecture these complications will be discussed: how to recognize them, how to manage them and how to, if possible avoid them.

Keynote 11
Sobota 21. května 2022 / Saturday, May 21, 2022
14:50–15:20

How to understand and manage ankylosis after autotransplantation of teeth in growing patients

Lars Andersson

Root resorption is sometimes seen after autotransplantation of teeth. While infection related root resorption today can be prevented or treated, ankylosis is still considered to be the most serious long term complication for the tooth resulting in progressive replacement resorption of the root and eventually causing loss of the tooth. Moreover, inhibition of growth and development of the alveolar process is also seen in young growing patients following ankylosis. The lecture will give a complete overview aiming at understanding the development, progression and management of ankylosis based on in vivo- and clinical studies and an overview of the literature. An overview of various less successful methods to manage ankylosis will be given and the method of choice today, decoronation, will be presented. The recent shift in paradigm from "save the tooth" to "preserve the bone" will be elucidated.

Keynote 12
Sobota 21. května 2022 / Saturday, May 21, 2022
15:50–16:15

Examination of the evidence base for tooth autotransplantation

Sophy Barber

In this lecture, the current evidence base for tooth transplantation will be examined, including the reporting of population, intervention and outcomes. The importance of collecting unbiased data and including patient-reported experience and outcome measures will be discussed. Finally, the benefits and challenges of collecting agreed standardised data prospectively from all patients as an alternative to experimental studies will be outlined.

Keynote 13
Sobota 21. května 2022 / Saturday, May 21, 2022
16:50–17:15

Trans-alveolar autotransplantation of ectopic teeth

Paweł Plakwicz

Autotransplantation has become a well-established treatment option to replace missing teeth in growing patients. Gentle removal of the developing donor tooth seems to be the most important prognostic factor for normal healing after transplantation. For this reason, in case of ectopic position of the donor tooth, transplantation is not always possible immediately or even ever. In most cases the surgical access to the ectopic tooth is limited and makes the surgery unpredictable. Equally often the recipient site is too narrow to accommodate the transplant. Thus, in selected cases pre-surgical orthodontic treatment is often necessary to expand adequate space between neighboring teeth and to create conditions required for gentle surgery. Developing ectopic premolars and canines are the most common types of teeth which may be transplanted from their ectopic position to normal place in the dental arch, however attempts to transplant developing ectopic incisors or mature canines are also being made. The lecture will present the current treatment methods for ectopic teeth with an emphasis on autotransplantation, its predictability and long-term outcomes. Examples of the treatment will be presented and their outcomes will be discussed in relation to the success criteria and available studies.

MSP LECTURES

MSP 1
Pátek 20. května 2022 / Friday, May 20, 2022
12:20–12:30

Tooth autotransplantation tenting graft method for alveolar ridge augmentation: innovative technique and case series

Eduardo Yugo Suzuki, Thongnard Kumchai, Boonsiva Suzuki
Department of Orthodontics, Faculty of Dentistry, Bangkokthonburi University, Thailand

Aims: The periodontal ligament (PDL) has the unique ability to perform osteoinduction. Moreover, this property can be significantly enhanced by the pre-application of orthodontic loading. The purpose of this study was to evaluate the effectiveness of using pre-loaded tooth autotransplantation (TAT) in combination with particulate bovine-derived xenograft and concentrated growth factors (CGF) membrane, in a "tenting" fashion, to augment severely atrophic alveolar ridge defects. The new augmented ridges are used for both TAT and orthodontic tooth movement.

Materials: This prospective case study evaluated augmentation in five consecutive patients with severely resorbed alveolar ridges. Before augmentation, all alveolar sites were considered inadequate for TAT or orthodontic tooth movement. Horizontal ridge augmentation was performed using pre-loaded TAT to tent out the soft tissue matrix and periosteum for the adjacent particulate xenograft and CGF membrane. The ridges were evaluated using CBCT images at pre- and 3 months post-operative.

Results: Successful alveolar ridge augmentation with adequate horizontal width for TAT and orthodontic tooth movement was obtained. Augmented ridges became a recipient site for TAT and orthodontic tooth movement. Linear analysis of the width and volume of the recipient area at different time points revealed a final average increase in width was 5.9 ± 2.2 mm and a volume gain of 8.5 ± 3.2 mm3. All augmented ridges had retained their functional and esthetic integrity at 1 year after original augmentation.

Conclusions: Alveolar ridge augmentation using the tenting of the periosteum and soft tissue matrix using pre-loaded TAT maintains space and minimizes resorption of the particulate xenograft volume. This innovative technique offers a predictable functional and aesthetic reconstruction of localized defects without extensive amounts of autogenous bone.

MSP 2
Pátek 20. května 2022 / Friday, May 20, 2022
12:30–12:40

Smart Springs: a simple method to upright impacted mandibular third molars

Boonsiva Suzuki, Eduardo Yugo Suzuki
Department of Orthodontics, Faculty of Dentistry, Bangkokthonburi University, Thailand

Aims: Mandibular third molars are the most suitable donors for replacing a missing tooth by means of tooth autotranplantation (TAT). However, since they are routinely encountered impacted, they are difficult to retrieve and, therefore, unsuitable as donor teeth. This study introduces the development of Smart Springs to allow the controlled uprighting of impacted mandibular third molars (iM8s), therefore allowing their simple extraction.

Patients and methods: Sixty patients were enrolled and divided into three groups. In the miniscrew implant (MI8) group (n = 20), Smart Springs were anchored to miniscrews to apply uprighting forces to the iM8s. In the minimally invasive braces (MIB) group (n = 20), patients had the iM8s uprighted with aid of a reinforced MIB. In the control group (n = 20) iM8s were removed by traditional methods. Panoramic radiographs were recorded at the beginning (T0) and by the end of the iM8 uprighting (T1). Treatment duration for uprighting iM8s and total surgical time to extract the iM8s were recorded. Measurements of iM8 displacement and inclination were performed using custom-made software (Smart'n Ceph).

Results: All teeth were uprighted successfully. An average of 8 ± 2.5 weeks was necessary to upright the iM8s. The application of orthodontic force was significantly shorter in the MI8 group (6 weeks) than in the MIB group (8 weeks). No significant difference in the extraction duration between the MIB (1.4 ± 4.1 minutes) and MI8 (2.2 ± 2.1 minutes) groups was observed. No postoperative pain or discomfort was observed. In contrast, in the control group (28.4 ± 10.5 minutes) patients had experienced varying degrees of facial swelling, postoperative pain and trismus. The symptoms persisted for two to eight weeks.

Conclusions: Smart Springs anchored to either MI or MIB can minimize trauma to the iM8 thus allowing atraumatic extraction with benefits for TAT.

MSP 3
Pátek 20. května 2022 / Friday, May 20, 2022
12:40–12:50

Enhanced periodontal ligament following orthodontic tooth movement

Pattarin Promchaiwattana[1], Boonsiva Suzuki[1], Eduardo Yugo Suzuki[1], Suttichai Krisanaprakornkit[2]
[1]Department of Orthodontics, Faculty of Dentistry, Bangkokthonburi University, Thailand; [2]Center of Excellence in Oral and Maxillofacial Biology, Faculty of Dentistry, Chiang Mai University, Thailand

Aim: Mandibular third molars are frequently-used donor teeth for autotransplantation (TAT), however, they usually present in impacted positions, making them unsuitable for TAT. Applying orthodontic force to donor tooth before TAT leads to increased periodontal ligament (PDL) width, simplified extraction, and reduced risk of root resorption after TAT. This study aimed to examine amounts of PDL tissue on root surfaces of extracted third molars after applying an uprighting force, and to examine amounts of PDL attachment at tension and compression sites after uprighting.

Subject: Fifteen mesio-angulated mandibular third molars from 15 patients, planned for orthodontic extraction, were uprighted using springs connected to miniscrews, while 15 non-opposing and fully erupted mandibular third molars from the other 15 patients, received no force application, served as controls.

Methods: Altered angulation of uprighted teeth was assessed from panoramic radiographs. They were uprighted to an angulation, which enabled a simple extraction. All 30 molars were stained with toluidine blue to determine percentages of stained PDL on the root surfaces. The percentages of overall stained PDL areas, on three portions (cervical, middle, apical), and on four surfaces (buccal, lingual, mesial, distal) were compared between uprighted and control teeth.

Results: The mean percentage of stained PDL on the loaded teeth was greater than that on the unloaded teeth ($p<0.05$). The mean percentages of stained PDL were significantly increased at cervical and middle thirds, and buccal, mesial and distal surfaces of the loaded teeth compared to those of the unloaded teeth, whereas the apical third and lingual surface, corresponding to the compression sites, showed no significant increase.

Conclusions: Orthodontic tooth movement results in the PDL enhancement on all radicular surfaces. The application of orthodontic force before tooth extraction may be beneficial for increasing the success rates of TAT.

MSP 4
Pátek 20. května 2022 / Friday, May 20, 2022
16:00–16:10

The use of CBCT guidance for tooth autotransplantation in children – Part I: 3D planning in the artificial intelligence era, 3D printing and 3D patterns of healing

Mostafa EzEldeen[1,2], Jan Wyatt[2], Pierre Lahoud[1], Maria Cadenas de Llano-Pérula[3], Reinhilde Jacobs[1,4]
[1]OMFS IMPATH Research Group, Faculty of Medicine, Department of Imaging and Pathology, KU Leuven and Oral and Maxillofacial Surgery, Leuven, Belgium; [2]Department of Oral Health Sciences, KU Leuven and Paediatric Dentistry and Special Dental Care, University Hospitals Leuven, Leuven, Belgium; [3]Department of Oral Health Sciences-Orthodontics, KU Leuven and Dentistry, University Hospitals Leuven, Leuven, Belgium; [4]Department of Dental Medicine, Karolinska Institute, Stockholm, Sweden

Introduction: Tooth autotransplantation (TAT) offers a viable biological approach to tooth replacement in children. To enhance the outcome predictability of the TAT procedure, a cone-beam computed tomographic (CBCT)- guided surgical planning and transfer technique has been developed.

Objectives: To optimize the CBCT scanning protocol to achieve a dose as low as possible and to maintain sufficient image quality specific for tooth autotransplantation planning and follow-up, to develop a tooth segmentation tool based on convolutional neural networks (artificial intelligence), to evaluate the 3D patterns of healing after transplantation.

Methods: A general linear mixed model was fit to combine image quality parameters and radiation effective dose (ED) from 18 different exposure protocols in order to rank and compare all the protocols examined in the study. Pre and post-operative CBCT images (n= 44, follow-up period = 1-10 years) were analyzed using a novel method analyzing 3D hard tissue change of transplanted teeth then subjected to principal component analysis (PCA) and cluster analysis.

Results and conclusion: The ED for the pre-operative scan can be reduced to the range of 74.6-157.9 µSv. ED for the post-operative scan can be reduced to the range of 24.2-41.5 µSv. The following measurements were extracted from the 3D analysis: root hard tissue volume (RV), root length (RL), apical foramen area (AFA), and mean and maximum dentin wall thickness (DWT). PCA identified the mean DWT, RV, and maximum DWT as the parameters best describing tissue change after TAT. Cluster analysis applied to the variables chosen by the PCA classified the CBCT group into 4 distinct clusters revealing different patterns of post-TAT tissue healing. A considerable reduction in the pediatric effective dose can be achieved while maintaining sufficient image quality for tooth auto-transplantation planning and follow-up using elaborated dose optimization protocols.

MSP 5
Pátek 20. května 2022 / Friday, May 20, 2022
16:10–16:20

The use of CBCT guidance for tooth autotransplantation in children – Part II: Surgical technique, follow-up, short and long-term treatment outcome

Jan Wyatt[1], Mostafa EzEldeen[1,2], Maria Cadenas de Llano-Pérula[3], Reinhilde Jacobs[2,4]
[1]Department of Oral Health Sciences, KU Leuven and Paediatric Dentistry and Special Dental Care, University Hospitals Leuven, Leuven, Belgium; [2]OMFS IMPATH Research Group, Faculty of Medicine, Department of Imaging and Pathology KU Leuven and Oral and Maxillofacial Surgery, Leuven, Belgium; [3]Department of Oral Health Sciences-Orthodontics, KU Leuven and Dentistry, University Hospitals Leuven, Leuven, Belgium; [4]Department of Dental Medicine, Karolinska Institute, Stockholm, Sweden

Introduction: Tooth autotransplantation (TAT) offers a viable biological approach to tooth replacement in children. To enhance the outcome predictability of the TAT procedure, a cone-beam computed tomographic (CBCT)-guided surgical planning and transfer technique has been developed.

Objectives: To evaluate the outcome of CBCT-guided autotransplantation technique. To compare the outcome of CBCT-guided surgical planning and transfer technique for tooth autotransplantation versus conventional autotransplantation.

Methods: Total of 65 pediatric patients received CBCT-guided TAT in the period between 2007-2019. A controlled prospective clinical trial design was followed including a total of 88 subjects in whom 100 teeth were included following. The study group (n= 44, mean age 10.7± 1.1 years) underwent CBCT imaging for surgical planning and transfer via stereolithographic tooth replica fabrication, the historical control group (n= 44, mean age 10.6± 1.3 years) was subjected to conventional autotransplantation.

Results and conclusion: Overall survival rate for the CBCT-guided TAT was 92% and success rate was 86% compared to an 84% survival rate and a 78% success rate for the conventional group. Differences between both groups were not statistically significant (P > 0.05). The PDL and pulp-healing rates for the CBCT group were 86% and 92%, respectively, compared to 82% and 88% for the conventional group. Differences between both groups were not statistically significant (P > 0.05). The use of the tooth replica reduced the number of repeated attempts of repositioning the donor tooth to 0 to 3 attempts for the CBCT group compared to 4 to 7 attempts for the conventional group. TAT is a viable option for permanent tooth replacement in children and adolescents. The CBCT-guided approach simplified the surgery and increased the predictability of the treatment.

MSP 6
Pátek 20. května 2022 / Friday, May 20, 2022
16:20–16:30

History of tooth transplantation in Czech Republic

Starosta Martin[1,2]
[1]Collegium Dentalis, Olomouc, Czech Republic; [2]First faculty of medicine, Charles University, Prague, Czech Republic

The idea of replacing diseased or missing tooth has been around for millennia. One of the treatment possibilities is tooth transplantation. The basic studies about tooth transplation or rather autotransplantation were done in the last decade of the 20th century by Andreasen and Paulsen. What was the evolution of tooth transplantation in Czech Republic? We made a research in Czech dental literature through articles published in specialized journals: Zubní lékařství, Československé stomatologie, Praktické zubní lélařství, Česká stomatologie, Ortodoncie, LKS. The final results and conclusion will be discussed in this lecture.

MSP 7
Sobota 21. května 2022 / Saturday, May 21, 2022
12:00–12:10

Autotransplantations of impacted teeth, indications and treatment limits

Karin Klimo Kaňovská[1], Pavlína Černochová[2], Miroslava Fuchsová[3]
[1]Department of Oral surgery, Dental Clinic, Faculty of Medicine, Masaryk University, Brno, Czech Republic; [2]Department of Orthodontics, Dental Clinic, Faculty of Medicine, Masaryk University, Brno, Czech Republic; [3]Faculty of Medicine, Masaryk University, Brno, Czech Republic

Impaction of the teeth is one of the most common diagnoses we deal within orthodontics and orthodontical surgery. In most cases we use the method of surgical exposure but if is indicated one of methods, that can be used is a method of autotransplantation. We can use it in the situations of anomally placed impacted canines, where is not possible to do succesfully exposure to subsequent inclusion in the dental arch. In these cases we have been using for more than 15 years for the succesfull autotransplantation a biomodel, that is created based on the parameters obtained from CT analysis. The biomodel is made of sterilizable resin and helps us to create an artificial dental socket without damage of periodontal ligaments of the autotransplant. This method significantly reduces the risk of complications, especially ankylosis. In the case of unfinished development of the root of the transplanted tooth, its endodontic treatment is even not necessary. Authors on several occasions show indications and contraindications of this method and results within the period of more than 15 years.

MSP 8
Sobota 21. května 2022 / Saturday, May 21, 2022
12:10–12:20

Use of computer-aided planning and rapid prototyping in autotransplantation of teeth in children

Deise Cunha[1], Renata Pittella Cancado[2], Marcos Flavio Ambrosio[2], Marco Masioli[2], Ana Dilza Viana Barroso[2]
[1]Associação Brasileira de Odontologia – ES, Brazil; [2]UFES, Brazil

Introduction: Autotransplantation of immature teeth has good survival rates, and has benefits over osseointegrated implants in the growing child, but is very technique sensitive.

Purpose: This study has the goal to describe the advantages in planning and execution of autotransplanted teeth with the use of Cone-bean tomography, computer-aided planning and rapid prototyping of the donor teeth, surgical splint and post-operative dental protection plate.

Methods: In young children with the loss of anterior superior teeth an orthodontic treatment was accomplished with the intend to prepare the receptor site. All this children had immature premolars that could be selected as the donor teeth. After that a Cone-bean tomography and an intra-oral scanning was done to produce a Dicon and a STL archive. These two archives were combined with the VistaDent 3D Pro 2.1 software. With this material a web conference was set via Skype with the orthodontist, the oral and maxillofacial surgeon and the technician of the prototyping company where the virtual planning were done. At this moment the donor teeth was select and the template of this teeth was prototyped along with the surgical splint. These two gadgets were used to more accurately prepare the donor site and to reduce the time between the removal of the premolar selected and its implantation. This surgical splint also was able to avoid post surgical occlusal trauma though the correct planned position of the teeth. All this advantages were able to reduce surgical time. Besides that an post operative dental protection plate was made and installed. This acetate plate was made after a post operative intra oral scanning.

Final consideration: This accurate virtually predesigned surgical templates could improve the prognosis of the autotranplantation in the future by full implementation of recommended guidelines, ensuring an atraumatic surgical protocol.

MSP 9
Sobota 21. května 2022 / Saturday, May 21, 2022
12:20–12:30

Adamantine tissue autograft: an alternative rehabilitation treatment for tooth transplantation

Alberto Teramoto Ohara
Universidad Tecnológica de México & Universidad Latinoamericana, Mexico City, Mexico

In almost all transplantation cases, after surgical procedure the crown of the teeth need to be reshaped to provide function and esthetics into its new arch position. The traditional way to get it is with either composite resin or porcelain laminate veneer, however those materials do not possess the ideal natural properties of a dental tissue, for this purpose the most achievable biocompatible material for replacement this dental structure must be the same natural enamel tissue.

MSP 10
Sobota 21. května 2022 / Saturday, May 21, 2022
12:30–12:50

Primary tooth autotransplantation: Looking back on 15 years of clinical practice

Dirk Nolte[1,2], Claudia Tschammler[3], Florian Hoss[4]
[1]Practice Clinic of Oral and Maxillofacial Surgery, Munich, Germany; [2]Associate Professor of OMF Surgery at Ruhr-University of Bochum, Germany; [3]Institute of Medical Biometry and Informatics, University of Heidelberg, Germany; [4]Department of Orthodontics, Hannover Medical School (MHH), Germany

Autogenous primary tooth transplantation is a surgical technique that can be used to replace missing or traumatically lost teeth already in the early mixed dentition (from the age of 7 -10). The prerequisite for this method is the presence of still sufficient root length of the existing deciduous teeth, preferably the primary canines. In the case of dental aplasia, only those primary teeth that are at risk of resorption by the erupting permanent tooth can be considered for transplantation. The surgical technique, first published in 2015 and followed by a retrospective case study in 2021, represents a temporary measure that takes advantage of the naturally exfoliation of the deciduous teeth. After meanwhile more than 90 primary canine transplants performed to date it can be concluded that both soft tissue and bone growth in the area of the aplastic or traumatically lost tooth are effectively supported by this method. With a mean graft survival time of 7.2 years and a 5-year survival rate of approximately 87%, the technique is safe and predictable. Patient satisfaction with this method has been rated very good to good by the German school grades, underlining the acceptance of this new technique. Clinical case studies on both dental aplasia and traumatic tooth loss in young children (aged 7 to 10) will report on the long-term follow-up and continued fate of the grafts over the past 15 years of clinical practice.

MSP 11
Sobota 21. května 2022 / Saturday, May 21, 2022
14:25–14:35

Autotransplantation and complications: case presentations

Manuela Daian[1], Michalis Pantaleon[1], Anna Louropoulou[2], Anastasios Pantaleon[3]
[1]Orthodontie Oud-Beijerland, Netherlands; [2]ParoRotterdam, Netherlands; [3]Danube Private University, Austria

During the years, autotrasplantation has proved to be a reliable treatment method. The possibility of treating young patients with the help of autotransplantation has a major advantage: the autotransplanted tooth promotes bone formation and can be used in growing patients. In the past years, autotransplantation has been widely performed, and many publications have reported that the survival rate of transplanted teeth may be as high as 90% (Andreasen JO, Paulsen HU, Schwartz O). However, some undesirable complications, such as root resorption or dentoalveolar ankylosis, still exist. Many factors influence the result, such as: the developmental stage of the tooth, donor type, adequacy of bone support at the recipient site, the duration of extraoral exposure of the donor tooth during surgery, damage to the root cementum and the periodontal ligament, and the experience of the oral surgeon (Schwartz, O, Ahlberg, K.) The results of Yusuke Suzakia et al also showed that the increase of root resorption coincided with the disruption of the PDL attached to the root after extraction. The larger the exposed root surface was, the more extensively the root resorption or dentoalveolar ankylosis might occur (Andreasen JO, Lindskog S et al). In addition, cementoblasts are involved in the regeneration of resorbed tooth substances. Thus, the extraction of teeth with a thinner PDL may also injure the cementoblasts, which results in the inhibition of repair of the root after replantation (Sasaki T et al). Our clinical experience has showed that after autotransplantation careful monitoring of the pulp and PDL healing is very important. However, in some cases, the patients experienced a transitory ankylosis and in some cases the teeth failed to respond to the orthodontic forces, thus an alternative treatment plan had to be followed.

MSP 12
Sobota 21. května 2022 / Saturday, May 21, 2022
14:35–14:45

Success criteria and methods for evaluating the success of autotransplanted teeth

Fernanda Nunes[1], Joao BG Intra[1], Marcos Frozoni[2], Armelindo Roldi[1], Natalia Coutinho[1]
[1]Brazilian Association of Dentistry, Brazil; [2]Faculdade Sao Leopoldo Mandic, Brazil

Objective: to discuss the ideal criteria and methods to evaluate the success rate of autotransplanted teeth for the anterior region of the maxilla.

Material and Methods: a retrospective study carried out in 33 patients, who had 44 teeth autotransplanted to the anterior region of the maxilla. Patients were evaluated through medical records, clinical and radiographic examination, according to the following success criteria: absence of pain (spontaneous and provoked), absence of severe periodontitis, absence of periapicopathy, absence of internal and external resorption, absence of ankylosis, and root development.

Results: 44 teeth were autotransplanted, being 12 upper premolars, 31 lower premolars and 1 canine. Most were transplanted to replace upper central incisor teeth lost by trauma, and 1 replaced the lateral incisor due to agenesis. The follow-up period ranged from 6 months to 25 years. The age of patients at the time of surgery ranged from 7 to 15 years. The success rate obtained was 79.6 %. One tooth was lost and 43 teeth were present, some with signs of failure. In the analysis of medical records, some computed tomography scans were present, helped in the diagnosis of failure.

Conclusion: Tooth autotransplantation is a viable treatment for replacing anterior teeth in young patients. The success criteria for tooth autotransplantation should be discussed and standardized by the scientific community. The computed tomography exam must be inserted in the methodology of success assessment.

MSP 13
Sobota 21. května 2022 / Saturday, May 21, 2022
16:20–16:30

A Clinical research of surgical uprighting for impacted lower second molar

Yusuke Matsuzawa, Tetsuro Yamashita
Department of Oral and Maxillofacial Surgery, Keiyukai Sapporo Hospital, Japan

Purpose: Surgical uprighting is one of the treatment options for impacted lower second molars. However, although there are several case reports. We conducted this study to understand the actual situation of surgical uprighting and to clarify the treatment results.

Materials and methods: We surveyed patient's outline and treatment result for cases which performed surgical uprighting at Hokkaido University Hospital and Keiyukai Sapporo Hospital from 2011 to 2018. For the cases of Hokkaido University Hospital, we evaluated with X-ray picture. The inclination angle of the tooth axis before and after operation on the orthopantomogram was measured. And the improvement rate of inclination angle were calculate.

Results: The subjects were 22 cases and 27 teeth. The age at operation was 12 years and 3 months to 19 years and 11 months. The case that performed two times of surgical uprighting was six. The stage of root development according to the Moorrees's classification at the time of operation was 9 teeth in stage 5, 11 teeth in stage 6, and 7 teeth in stage 7. The impacted state was 21 teeth with mesial inclination, 2 teeth with lingual inclination, and 4 teeth with infraocclusion. Two cases were devitalized after operation. The X-ray evaluation was performed in 14 teeth in 12 cases. The preoperative inclination angle was 31 to 80 ° (average 52.1 °), the postoperative inclination angle was 1 to 56 ° (average 36.3 °), and the improvement rate was 12.1 to 96.8 % (average 44 %).

Discussion: Surgical uprighting is short treatment duration and has the advantage of being able to cope with cases in which orthodontic uprighting is difficult, but also has drawbacks such as the need for surgery and the possibility of devitallization. In this study, two cases were devitallized, and a quarter of the cases required twice operations, but generally good results were obtained.

MSP 14
Sobota 21. května 2022 / Saturday, May 21, 2022
16:30–16:40

Autotransplantation into the atrophied alveolar process of the distal segment of the mandible

Michal Novosad[1], Ivo Marek[1,2], Lenka Ježková[1]
[1]Stomatologic centre Břeclav, Czech Republic; [2]Department of Orthodontics, Palacký University, Olomouc, Czech Republic

The autotransplantation of a tooth into an atrophied alveolar process presents many difficulties. Success requires a suitable indication, as well as correct surgical protocol, including careful follow up. To avoid possible complications of the surgical procedure, it is necessary to respect the morphology of the root and the anatomy of the locus into which the tooth is to be transplanted. In patients whose lower dental arches are shortened due to tooth extraction, the change caused by atrophy is particularly prominent; and the same applies to changes in the soft tissues, with attached gingiva disappearing. Horizontal atrophy of the alveolar process is often accompanied by vertical bone loss. When the bone on offer is so limited, surgery and the subsequent fixation of the tooth is more difficult. However, using the correct surgical procedure, it is possible to perform autotransplantation even into an atrophied alveolar process, thus avoiding implantation and augmentation. Using several examples, the authors demonstrate the indications, the step-by-step surgical procedures, and the difficulties involved in transplanting a tooth into a shortened lower dental arch.

MSP 15
Sobota 21. května 2022 / Saturday, May 21, 2022
16:40–16:50

Intra-alveolar transplantation: surgical extrusion

Ladislav Gregor
Dentální klinika Sorriso, Brno, Czech Republic

Surgical extrusion should be considered as a treatment option when thinking about restorability of teeth that have insufficient coronal tooth structure remaining due to deep caries, resorption or traumatic injury. We would like to describe our approach to the surgical extrusion including also the prosthodontic management in detail and discuss the advantages and disadvantages compared to alternative approaches, including surgical crown lenghtening and orthodontic extrusion.

POSTERS

Poster 1

Endodontic management of autotransplanted teeth

Badalyan Kristina [1,2], Stepanyan Zara[1] , Zedgenidze Alena[1], Possesor Andrey[1]
[1]Central Research Institute of Dental and Maxillofacial Surgery, Department of Dental surgery and experimental implantology, Moscow, Russia; [2]Private dental practitioner in Legeartis Dental Clinic, Moscow, Russia

Abstract: The effectiveness of tooth replantation were studied in order to reduce surgical trauma. The study was conducted on 18 patients diagnosed with „chronic apical periodonitis" and „cyst". According to the results of the study, tooth replantation was recognised as one of the most optimal and non-traumatic tooth-preserving operations.

Methods: 18 patients (8 men and 10 women) underwent tooth extraction and replantation with clinical diagnoses: „chronic periodontitis". The diagnosis were based on the clinical pictures and radiography data. Subjective postoperative feelings were evaluated on a visual-analogue scale (VAS). Tooth stability was determined by Periotest 6 months post surgery. The index values range from -8 to +50. According to the degree of mobility, the indexes are distributed as follows: 0 degree – from -8 to +09; I degree – from +10 to +19; II degree – from +20 to +29; III degree – from +30 to +50.

Observation: In the early and remote postoperative period, no patients had significant complications. The average of pain by the visual-analogue scale were recorded at 2-3 points on the 3rd day. When visiting 6 months post surgery, clinical and radiological studies showed satisfactory functional and aesthetic results. Also, 6 months after surgery, all patients were diagnosed with Periotest. The indicator ranged from -0.8 to +0.9, which according to the table of the device, indicates lack of mobility in the examined teeth.

Conclusion: Based on the analysis of patient data, the indications for replantation:

- impossibility/unpredictability of root canal treatment;
- difficult access during resections and retrograde sealing with a high probability of damage to anatomical structures (e.g.second molar of the lower jaw);
- probability of large bone defects and loss of tooth functionality during endodontic surgery (e.g. lower jaw incisors). Replantation is one of the possible dental preservation operations, which allows you to maximise the preservation of body tissues, increasing the effectiveness of treatment, and significantly reduces the intensity of postoperative pain, the risk of postoperative complications and reduces the overall period of rehabilitation for patients.

Poster 2

Case report: Reconstruction of missing frontal teeth with autotransplantation and mesialization

Peter Dírer[1], Barbora Vágnerová[2], Zdeněk Pokorný[3]
[1]Department of Orthodontics, FN Olomouc, Czech Republic; [2]Department of Prosthetics, FN Olomouc, Czech Republic; [3]Department of Periodontology, FN Olomouc, Czech Republic

Aims: Reconstruction of lost central incisor with autotranplantation in a growing patient is one of the few possible ways, how to treat this defect. Parallel orthodontic anomalies could complicate creating appropriate treatment plan. The aim of this presentation is to describe the treatment of patient with lost upper central incisor combined with agenesis and teeth retention.

Subject and method: An 11-year 11-month-old boy with missing tooth 11, which was traumatically lost 6 years ago. Tha patient is suffering from agenesis of teeth 12 and 22, closed space for teeth 15 and 43, the eruption of 13 in reg. 11 and persisting deciduous tooth 53. Angle class II. molar relationship. As a treatment plan, it was decided to reconstruct missing teeth with canine mesialization and tooth autotransplantation instead of prosthodontic solution with bridges or removable prostheses. For better visualization, model setup was made.

Results: Treatment started with creating space for transplantation with distalization of 13 into reg. 12. As donor was chosen tooth 45, whose removal created space for retained tooth 43. Space for 15 was created with distalization of 16 and mesialization of 14 into reg. 13. After alignment, canines were reshaped to lateral incisors, transplanted premolar to central incisor and first premolars to canines – noninvasively with direct composite veneers.

Conclusion: Considering growth, reconstruction of missing frontal teeth in children is challenging. Tooth autotransplantation is one of the few possibilities, how to treat this condition with stable results. Close cooperation between an orthodontist, surgeon and prosthodontist is necessary.

Poster 3

Therapy of primary failure of eruption (PFE) using autotransplantation of teeth – a case report

Anastázie Homolová[1], Peter Dírer[1], Martin Starosta[2]
[1]Department of Orthodontics, Palacky University, Olomouc, Czech Republic; [2]Department of Periodontology, Palacky University, Olomouc, Czech Republic

Aim: Primary failure of eruption (PFE) is very rare in general population, however there may be much higher percentage of occcurence in orthodontic office. The aim of this paper is to present a solution to this problém by using autotransplantation of teeth.

Subject and methodology: The patient was a 16-year old woman suspected of PFE of tooth 37. The upper and lower dental arch relationship was Angle I class with crowding in both frontal segments, supernumerary teeth 19 and 29 were present. The set treatment plan included extraction of teeth 19, 29, 37, 38, 48 in under general anesthesia, healing time of a large defect of region 37, orthodontic fixed apliance therapy with IPR in both dental arches followed by extraction of 29, autotransplantation of tooth 28 to site 37 and its root canal treatment (RCT).

Result: Orthodontic treatment started with upper fixed appliance, followed by autotransplantation and 2 weeks later RCT. Later the lower appliance was fixed and the transplanted tooth was fixated. Healing proceeded without complications. Orthodontic therapy solved all initial problems – crowding, midline shift and deep bite. Also intrusion in the upper left lateral segment was done to prevent early contact with the transplanted tooth. Final composite filling of the crown of tooth 37 was made after the fixed appliance removal.

Conclusion: In case of PFE, autotransplantation is a method of choice. This type of therapy provides enormous benefits and considering the young age of most patients, it is advisable to offer this option as a prefered one.

Poster 4

Management of complications after autotransplantation of premolars

Petra Jůnová[1], Hana Böhmová[1], Petr Pošta[2], Miroslava Chalupová[3]
[1]Stomatologická klinika LF UK a FN Plzeň, Ortodontické oddělení, Česká republika; [2]Stomatologická klinika LF UK a FN Plzeň, ÚČOCH, Česká republika; [3]Stomatologická klinika LF UK a FN Plzeň, konzervační oddělení, Česká republika

Purpose: To present treatment options for post-autotransplantation root resorption. In the patient (aged 12 years) with agenesis of the teeth 45 and 35, the tooth 15 was indicated for autotransplantation to position 45 and the tooth 25 to position 35.

Results: 6 weeks after the surgery, signs of aggressive external resorption were observed in both the teeth. In the tooth in position 45 resorption reached the root canal. In the tooth in position 35 surface resorption in the cervical area of the tooth was observed.

Treatment: The condition of the tooth 45 was managed through RCT and Biodentine filling. In the tooth 35, revision surgery, raising of the mucoperiosteal flap, root defect revision and filling with MTA were performed.

Conclusion: The condition was assessed after 11 months. Both the teeth are functional, the tooth 35 is vital. Both the teeth were aligned, so far with no signs of evolving resorption. Long-term follow-up is necessary.

Poster 5

Autologous dental bioprothesis, presentation of a clinic case

Moreno Hernandez, JR
Teachers holder Area of Oral and Maxillofacial Surgery, Faculty of Dentistry, University of El Salvador.

Objective: Transplantation of third molars, such as Autologous Dental Bioprosthesis in patient with exodontics of lower permanent molars.

Introduction: Autologous dental bioprosthesis (BDA) consists of the transfer of a tooth from one particular position to another in the same patient, these teeth are usually those that by their position in the arc are not functionally active (included, retained or erupted), which are moved into the alveolar space of a recent extraction or a surgically created tooth alveolus. For young patients, BDA is performed with fully formed teeth or tooth germs. In the present case the use of the third molars as biologically transplanted tooth parts in the same patient is shown covering a 2-year case control period, and performed in two surgical times and with different techniques transplant surgical: the immediate technique for part 4-8 towards the dental socket 4-7 and the two-step technique of 2-8 towards the dental socket 3-6.

Methodology: A bibliographic review of the different BDA techniques was carried out. Once the theoretical criteria (surgical protocol) were defined, the application phase of the technique was carried out, with the criterion of one or two teeth indicated for extraction. The patient candidates for this treatment, should have the following characteristics: Patient wholly healthy, without diagnosed systemic disease. Arrangement of the patient to carry out the proposed technique. Adequate oral hygiene. Complementary tests (Laboratory and image).

Clinical case: Female patient of 26 years of age who consults at the Faculty of Dentistry of the University of El Salvador, healthy patient and referred by orthodontist for exodontics of third molars upper and lower, explains the techniques of BDA and accepts perform them on the condition that they do not give up treatment.

Results: During the X-ray checks of the BDA, no internal or external reabsorption, or obliteration of the pulp chamber, was observed. Absence of dental mobility, and complete

reintegration of donor teeth.The clinical control of the patient was applied the endodontic test (table No. 1) included in the clinical sheet of the faculty evaluating in each tooth: pain, thermal, electrical tests, clinical examination and radiographic considerations with positive results.

Conclusions: Proper patient selection ensures the success of this technique. The most commonly transplanted donor teeth correspond to the third molars. Prostodontically a restoration of occlusion. Low cost.

Poster 6

Autotransplantation of 2 teeth in the same patient (28 and 38 in loco 26 and 36), 2 years follow-up

Oleksii Siedakov, Natalia Siedakova
Premium Dental Care, Prague, Czech Republic

Objectives: After tooth extraction, restoration of dentition integrity becomes an issue. Tooth autotransplantation is an effective and reliable method which also requires coincidence of conditions determining success of the treatment. It also includes the presence of a suitable „candidate" for transplantation in the place of the extracted tooth. In this clinical case we present autotransplantation of two teeth (28 and 38 instead of 26 and 36) in the same patient and a two-year follow-up.

Material and methods: Patient E. T., born 1986, generally healthy, without chronic medication, non-smoker, came to our office for dental examination and treatment. Clinical and X-ray examinations revealed carious lesions of teeth 26 and 36 which were indicated for extractions, as well as semi-impacted teeth 18,28,38,48. Considering the localization of teeth 28, 38 as well as indication for extractions, it was decided to perform autotransplantation of the teeth 28 and 38 in the area of 26 and 36. The teeth 26 and 36 were extracted atraumatically, dental alveoli were rinsed with CHX 0.2 % solution, afterwards the teeth 28 and 38 were extracted in gentle way, paying attention not to damage the area of the roots, then preparation of recipient sites in loco 26 and 36 was performed to ensure congruence with transplanted teeth 28 and 38. After the transplantation, tooth 28 was fixed with a splint (orthodontic wire + photo composite) and tooth 38 – with a non-absorbable monofilament suture 5/0, which was replaced with a splint on the 5th day after the surgery. Endodontic treatment of the transplanted teeth was performed in 2 days after AT 28 in loco 26 and in 5 days after AT 38 in loco 36. In both cases, the procedures were followed by uncomplicated healing, removal of splints, build-ups, and delivery of adhesively cemented all-ceramic crowns.

Results: The clinical outcome (incl. X-ray) is stable both in functional and aesthetic aspect 25 months after AT of 28 in loco 26 and 38 in loco 36. Tooth autotransplantation can be a reliable alternative to dental implants. Correct indications and treatment performed lege artis are crucial factors for successful treatment outcome.

Poster 7

Replantation of the second molar of the upper jaw with a longitudinal root fracture

Nikolai Igorevich Vasiliev
Izhevsk State Medical Academy Department of surgical dentistry and maxillofacial surgery, Izhevsk, Russia

The presentation shows the experience of replanting the second molar on the upper jaw with a longitudinal crack of one of the roots. A clinical case further complicated by periapical lesion and proximity of the maxillary sinus.

The patient was concerned about periodic pain in the tooth when chewing. During the replantation operation, a thorough evacuation of the periapical lesion, retrograde filling of the root apexes, and rigid mobilization of the replant were performed. The replanted tooth is set with an offset in the coronal direction for a more predictable overlap of the crack boundary with the future ceramic crown. 2 months after the operation, a stable position of the tooth, a stable state of the surrounding soft tissues, and the beginning of the formation of the native bone in the periapical zone were obtained. Ceramic crowns are installed on the teeth after 3 months.

After 6 months of replantation, bone restoration was observed on an x-ray image. More than half of the defect was radiographically filled with native bone. The dynamic positive dynamics of periapical bone restoration was confirmed by the complete absence of pain in the tooth and the absence of pathological tooth mobility. The successful functioning of the entire tooth is due to the rapid recovery of the ligamentous apparatus. Careful treatment of the tooth ligament during the replantation operation is an important nuance.

Poster 8

Ankylosis of autotransplanted premolar to the maxillary incisor position: a case report

Welford S.[1], Lugaric P.[2], Houghton N.[1], Mittal T.[3], O'Malley P.[2], Scott P.[2], Day P.[1]
[1]School of Dentistry, University of Leeds, United Kingdom; [2]Doncaster and Bassetlaw Teaching Hospitals NHS Foundation Trust, Department of Oral and Maxillofacial Surgery and Orthodontics, Doncaster, Unitek Kingdom; [3]South Tees Hospitals NHS Foundation Trust, Department of Orthodontics, Middlesbrough, United Kingdom

Background: Tooth autotransplantation can provide an effective biological replacement for central incisors following dental trauma, when options to restore the original tooth have been exhausted. Subsequent failure of the transplanted tooth can be challenging to manage. This case report describes the management of an ankylosed upper central incisor by autotransplantation of a premolar and subsequent ankylosis of the transplanted tooth.

Methods: A healthy 12 year old boy presented to the Leeds Dental Institute, UK with history of enamel-dentine fractures with lateral luxation injury to upper right and left central incisors at the age of 10. These had been immediately restored with resin composite, however, two years post-injury the upper right central incisor became ankylosed and had poor prognosis. The patient had Class II division 1 malocclusion on caries-free mixed dentition. Following assessment on the inter-disciplinary clinic the ankylosed upper right central incisor was extracted under general anaesthesia and a maxillary second premolar with incomplete root development transplanted to the socket. Orthodontic movement of the tooth with fixed appliance therapy was commenced three months after transplantation.

Follow up: Six months after transplantation, orthodontic movement of the transplanted tooth was unsuccessful due to ankylosis. Following further discussions of the treatment options, the ankylosed tooth will be decoronated in order to retain bone for likely implant replacement in the future. Fixed appliance therapy will be completed to correct the malocclusion.

Conclusion: Failure of tooth autotransplantation can present a significant challenge. It is essential that all options are presented to the patient from the outset, including the risk of failure. With careful attention to shared decision making and encouragement of full patient/parent engagement then compliance and dentist-patient relationship can be maintained, even in challenging circumstances.

Poster 9

The autotransplantation of upper impacted canines (case report)

Martin Starosta[1], Jozef Galbavý[2]
[1]Collegium Dentalis, Olomouc and First faculty of medicine, Charles University, Prague, Czech Republic; [2]AP Ortho s.r.o., Stará Turá, Slovakia

The maxillary canines play an important role in aesthetics and function; therefore, patients with impacted canine usually undergo more difficult and longer treatment than patients with other malocclusions. We deal with impacted maxillary canines in orthodontic departments quite often; on average 1.5%-2% of the population is affected. The buccal location of maxillary impacted canines is observed in 15% of cases. The treatment of impacted caninces mostly needs interdisciplinary cooperation betwen an orthodontist and a dental surgeon.The main task for the orthodontist is a creation of enough space for impacted caninen by fixed appliance. The main task for the surgeon is an expositon of the crown of the canine for orthodontic device by the method of fenestration, patefaction, apically positioned flap or another method of surgical exposure of canines crown. Neverthelees the orthodontic treatment in the meaning of right aligment of impacted canine can sometimes fail. In such situations, an autotransplantation could be considered. We present case report of this treatment in young girl.

Poster 10

The bone induction by autotransplantated tooth (CBCT proof)

Martin Starosta[1], Eliška Dohnalová[2]
[1]Collegium Dentalis, Olomouc and First faculty of medicine, Charles University, Prague, Czech Republic; [2]Private orthodontist, Olomouc, Czech Republic

It is commonly accepted that vitality of periodontal ligament of the autotransplanted tooth is basic step for uncomplicated healing. We know the periodontal ligaments capability of bone induction too but mostly only used during ortodontic movement of tooth. On the other hand we know osseoinductive effect of the autotransplantated teeth with vital periodontal ligaments placed into sinus lift. But the question is: Could we expect this osseoinduction in another situation then sinus lift? In this case report we demonstrate this osseoinductive effect by CBCT proof, 2 years after autotransplantation of upper premolar to lower jaw position.

Poster 11

The tooth replantation with Emdogain – treatment possibility of periodontally compromised tooth (case report)

Martin Starosta[1], Barbora Vágnerová[2]
[1]Collegium Dentalis, Olomouc and First faculty of medicine and Charles University, Prague, Czech Republic; [2]Collegium Dentalis, Olomouc, Clinic of dental science, Olomouc, Czech Republic

Current studies consider teeth autotransplantations and replantations as realiable methods of treatment. From the point of view of indication the autotransplantation may be performed in the following cases:
1) When the extracted tooth is placed into a different position.
2) When the position of a tooth is adjusted.
3) When the tooth is extracted, treated and returned into its dental alveolus (socket) again.

The common indication within orthodontic treatment autotransplantation is carried out in 1) and 2).

In this case report we used the third indication for tooth autotransplantation mentioned above. After the proper endodontic treatment, the periodontally compromised tooth was extracted and after the extraction, the socket and root surface of the tooth was cleaned. It means exccavation of granulation tissue from teh socket and scaling and root planing of the tooth. After that, the root of tooth was conditioned with EDTA, washed and covered by Emdogain. The tooth was replantated into its own socket and splinted. This technique seems to be a treatment possibility in the periodontally compromised tooth with poor prognosis.

Poster 12

Effect of orthodontic loading on the thickness of periodontal ligament proliferation

Issarintip Denkongpon, Boonsiva Suzuki, Eduardo Yugo Suzuki
Department of Orthodontics, Faculty of Dentistry, Bangkokthonburi University, Thailand

Aims: Periodontal ligament (PDL) plays a fundamental role in periodontal regeneration. This ability is significantly enhanced following orthodontic preloading and is advantageous for the success of tooth autotransplantation (TAT). The purpose of this study was to assess the changes of PDL thickness in extracted premolars following application of orthodontic loading.

Materials and methods: Fourteen patients, requiring premolars extraction, received orthodontic preloading for 4 and 8 weeks. Unloaded contralateral premolars were used as control. The extracted premolars were fixed with 10% buffered formalin and stained with 0.04% (w/v) toluidine blue. Premolars were embedded in acrylic blocks and then cross-sectionated in coronal, middle and apical regions. Digitized cross-sectional images were recorded under a stereomicroscope and the percentage of stained PDL was analysed using ImageJ software.

Results: Orthodontic preloading for 4 and 8 weeks significantly increased the percentage of stained PDL on the root surface compared to the control. However, the PDL thickness at 8 weeks was increase two-folded compared to 4 weeks ($p<0.05$). Although the thinnest PDL was observed at the middle region of the control, the highest increase of PDL thickness was also observed at the middle (4.6 times) region at the 8 weeks ($p<0.01$). The coronal regions also presented with a significant increase of PDL thickness (4.1 times) at the 8 weeks compared to control. The duration and difficulty of extraction were significantly reduced in preloaded than control unloaded teeth.

Conclusion: A 8-week duration of orthodontic preloading provides increase PDL thickness at the coronal and middle regions. Increased PDL thickness ease tooth extraction, and provide intact PDL coverage that might be advantageous for the success of TAT.

Poster 13

Altered bone biomarker expression in periodontal ligament upon orthodontic preloading

Sasathorn Phutinart[1], Boonsiva Suzuki[1], Eduardo Yugo Suzuki[1], Suttichai Krisanaprakornkit[2]
[1]Department of Orthodontics, Bangkokthonburi University, Thailand; [2]Center of Excellence in Oral and Maxillofacial Biology, Faculty of Dentistry, Chiang Mai University, Thailand

Aim: Preservation of periodontal ligament (PDL) is vital to the success of tooth autotransplantation (TAT). Orthodontic loading prior to the extraction increases PDL volume, thus improving success rates for transplantation. Additionally, orthodontic loading results in stimulation of various cells in the PDL including bone cells which may be essential in healing of TAT. Therefore, this study aims to evaluate the effect of orthodontic loading on human PDL, by determining the expression of bone biomarkers: osteoblast transcription factor, runt-related transcription factor 2 (RUNX2); and osteoblast marker, alkaline phosphatase (ALP) at different loading durations.

Subjects: Seventy-two first premolars from 18 participants (21.0±3.82 years) who required extraction for orthodontic treatment were recruited.

Methods: The premolars were randomly assigned into experimental groups that received orthodontic loading for 1, 2 or 4 weeks, and a control that received no loading. After extraction, the amount of PDL tissue proliferation was evaluated by toluidine blue staining. The expressions of the bone biomarkers were isolated from PDL of the extracted premolars and analyzed by immunoblotting and densitometry. The Friedman Test and Wilcoxon Signed Ranks Test were used for statistical evaluation.

Results: The percentage of stained PDL was significantly increased at two and four weeks compared to the unloaded ($p<0.05$). Varying expressions of RUNX2 and ALP were detected at their predicted sizes in both control and experimental groups. Compared to the control group, the expression levels of RUNX2 and ALP increased significantly at different time periods ($p< 0.05$).

Conclusions: The results demonstrate time-dependent nature of PDL alteration. Orthodontic preloading for four weeks enhances the amounts of PDL tissue together with RUNX2 and ALP expression. These may be beneficial to healing of TAT.

Poster 14

Autotransplantation of an immature tooth into sinus lift with the use of PRGF

Ivo Nekvinda[1], Zdeněk Hofman[2]
[1]Medical Centre Staňkova, Pardubice, Staňkova 1345, Czech Republic; [2]Hradec Králové, Veverkova 945/4, Czech Republic

One of the options for autotransplantation of an immature tooth into the maxillary lateral region in case of insufficient bone volume is the autotransplantation using the sinus augmentation technique (sinus lift). Sinus lift is an augmentation technique in implantology using the augmentation materials, contrary to the sinus lift in autotransplantation. In autotransplantation only PRGF (plasma rich in platelet and growth factors) is used for augmentation. When this technique is applied, of key importance is the cooperation between the surgeon and the orthodontist, 3D planning and correct timing. Based on our experience, the autotransplantation of an immature tooth into sinus lift with PRGF augmentation results in an increase of bone volume and completion of root formation.

Conclusion: Autotransplantation of an immature tooth into sinus lift with PRGF augmentation leads to the bone volume increase and completion of tooth development.

Poster 15

Challenging canines

Dagmar Marandi
Unimed Kaarli Dental Clinic, Estonia

Canines have a specific and unique role in the mouth and dentition, but they are often affected by severe eruption problems. From the functional aspect they are supporting the overall dentition, they guide the mandible when it moves. Canines are the second most frequently impacted teeth following third molars. Tooth may become impacted because of local factors, systemic factors or a genetic abnormality. Most often, the cause of impaction is inadequate arch length and space in which to erupt. Impacted upper canines affected approximately 2% of the population. It's impaction incidence is twice higher in maxilla than mandible. Bilateral impactions of canine have 8% of patients. Palatal impaction is more frequent, it affects about 85% of impacted maxillary canines. Approximately one third of impacted maxillary canines are positioned buccally. My case report presents the success of autotransplantation of maxillary canines and lower canines with almost closed apices and also shows the complications associated with malposition. I present some important cases from our everyday practise – 2 maxillary canines and 2 lower canines in children age 11...13 years. Patient age at transplantation is important, the success rate in open apices is higher. In our cases upper canines were impacted in horizontal position and lower canines were bilaterally impacted or impacted due to odontoma. All teeth were transplanted when root development was almost complete and no endodontic treatment was performed prior to or after implantation. The procedure is technique sensitive. Very important is atraumatic removal that maintains the viability of the periodontal ligament. In conclusion, I demonstrate the potential of aligning an extremely displaced canine, success, complications and survival in 4 years. Because of the aesthetic and functional importance of the canines, the autotransplantation is one of treatment opportunities.

Poster 16

Three-dimensional planning and efficiency of the use of surgical replicas in immature third molar autotransplantations. Operative results.

Miks Lejnieks[1,2], Ilze Akota[1], Gundega Jakobsone[1], Oskars Radzins[1,2], Laura Neimane[1,2]
[1]Riga Stradins University Institute of Stomatology, Riga, Latvia; [2]Baltic Biomaterials Centre of Excellence, Riga, Latvia

Aim: Since 2020, I have been working on the Baltic Biomaterials Centre of Excellence project to improve tooth autotransplantation survival and success rates. A pre-operative cone beam tomography is performed for all patients and a donor tooth replica is created and printed to reduce total surgery time, donor extra-alveolar time and the number of donor tooth fitting attempts. The aim of the study is to demonstrate immature third molar autotransplantation with and without a printed donor tooth replica. Surgeries were planned with BBCE and performed in the Institute of Stomatology, Riga Stradins University.

Methods: Two groups of immature third molar autotransplantation were described, one conventional and the second with a printed donor tooth replica. Total surgery time from first incision to last suture was taken, donor tooth extra- alveolar time was measured, and donor tooth fitting times were counted.

Results: Group 1. Convectional immature third molar autotransplantation. 22 patients, (average age 17.81, range 13–22). Average total surgery time – 65.91 min., donor tooth extra alveolar time 63.63 s, average fitting attempts – 2.00. Group 2. Surgery was done with printed donor tooth replica. 19 patients, (average age 16.10, range 14–19). Average total surgery time – 45.00 min, donor tooth extra alveolar time 61.32 s, average fitting attempts – 1.53

Conclusions: The use of a replica made the procedure less traumatic, reduced the total surgery time by 20.91 min, the donor extra-alveolar time by 2.3 s, and the number of times of fitting the donor tooth was reduced by 0.47 times. The study with the aim to investigate efficiency of cone-beam replicas is under way.

Acknowledgments: The authors acknowledge financial support from the European Union's Horizon 2020 research and inovation programme under the grant agreement No 857287

Presenting author's e-mail address: M.lejnieks@gmail.com

Poster 17

Autotransplantation of a tooth into a site with significant bone deficiency

Marek Pokorný[1], Marek Matoušek[2], Jiří Hálek[3]
[1]Complexdental s.r.o., Czech Republic; [2]Stomatologické centrum U svaté Anny, Brno, Czech Republic; [3]Rideto s.r.o., Czech Republic

Autotransplantation of teeth with completed root development as a method of replacing missing teeth in an adult patient is a predictable procedure. The osteoinductive properties of the transplanted tooth can be advantageously used in situations where the lack of bone complicates the insertion of an implant.

In the present case report, the patient had significant alveolar bone resorption due to advanced periodontitis and the presence of a massive radicular cyst in tooth 16. After extraction of the molar 16 in the upper dental arch and stabilization of the soft and hard tissues, tooth 28 was transplanted in place of tooth 16. The transplanted tooth was endodontically treated under OM, orthodontically extruded, rotated and prosthodontically fitted with a lithium-disilicate crown.

One and a quarter years after autotransplantation, the tooth is stable, free of ankylosis, with no evidence of root resorption on CBCT, and vertical bone growth along the roots of the transplanted tooth is clearly visible.

Poster 18

Increasing the effectiveness of mandibular molars root resection surgery using retrograde endodontic revision.

Kristina Badalyan, Stepanyan Zara, Posessor Andrey
Central Research Institute of Dental and Maxillofacial Surgery, Department of Dental surgery and experimental implantology, Moscow, Russia

Background: The purpose of the present study is to increase the effectiveness of mandibular molars apical root resection surgery. The present study included 21 patients with diagnosis "persistent apical periodontitis", "root cyst", in 11 of cases was performed surgery with less traumatic access formation that included using piezoelectric surgery system during formation and separation of cortical bone block and subsequent reposition after resection and retrograde root filling. The planning and performing of the surgery was described on the base of 2 clinical cases.

Methods: 21 patients with a diagnosis of „persistent apical periodontitis", „root cyst" was performed the clinical examination and surgical treatment. Patients were divided into 2 groups: § **Operation process. Group 1** included 11 patients which was performed surgery with less traumatic access formation achieved by using piezoelectric surgery system during formation and separation of cortical bone block and subsequent reposition after resection. The inclusion criteria was the presence of the dense mandibular cortical plate in the molars region. **Group 2** included 10 patients. The access to apical part of the roots during surgery was performed by using traditional technique. It means trepanation of the cortical plate in the projection of the root tips in the form of an oval or circle with a diameter of 5 to 10 mm by using mechanic handpiece, the speed of which is 150000-20000 rpm with obligatory sterile saline cooling to prevent overheating and burn of the bones. § **Postoperative period.** Patients of 2 group marked intense pain in first 3 days after surgery (level of the scale VAS was 5-7 points in 7 of 10 patients). Patients of 2 group had a high need for painkillers. Hyperemia and swelling of the mucosa in the area of intervention were observed in 7 patients, swelling of the face soft tissues was observed in 3 patients. Its severity on a scale VAS was 3-4 from 3 of 11 patients, Pain syndrome in patients of 1 group was observed on the day of operation and during next day, its severity was 3-4 points on VAS scale in 3 of 11 patients. Swelling and hyperemia of mucosa in region of intervention were observed 3 patients. Swelling of face soft tissue was not observed in this group. There were no complications like suture disruptions and high temperature. Severe complications in both group of patients were not observed in early and late postoperative period. Analysis of the periapical intraoral x-ray results in the second group showed a difference in bone density at 108±5 units, which indicates the tendency of bone regeneration in the region of surgery, but density decrease was also observed. The value of this criteria in the first group was significantly higher ($p<0.05$) with meaning 137±5, that shows a slight decrease in bone density after surgery and complete bonding of the bone block with the surrounding bone.

Conclusion: The results shows that technique that includes bone window closing by autograft is more effective and acceptable when resection of apical parts of molar roots is performed. The introduction into clinical practice improved technique of operative access can significantly reduce the intensity of postoperative pain, the risk of postoperative complications and reduce the duration of patients treatment.

Poster 19

Autotransplantation of premolar to replace ankylotic central incisor

MUDr. Ivana Dubovská Ph.D.[1], MUDr. Zdeněk Pokorný Ph.D.[1], MDDr. Barbora Vágnerová Ph.D.[1], MUDr. Wanda Urbanová Ph.D.[2]
[1]Institute of Dentistry and Oral Sciences, Faculty of Medicine and Dentistry, Palacký University, Olomouc, Czech Republic; [2]Department of Orthodontics and Cleft Anomalies, 3rd Medical Faculty, Charles University, Prague, Czech Republic

Premolar autotransplantation to the place of ankylotic central incisor is first choice treatment plan, particularly when the patient requires orthodontic treatment involving the extraction of immature premolars. Autotransplantation has been shown to have a high level of success and is accepted as a viable method for replacing teeth lost due to trauma (Slagsvold & Bjercke 1974, 1978a, b, Andreasen 1981, Kristerson & Andreasen 1984, Kristerson 1985, Andreasen *et al.* 1988). Case report shows 11years old patient with external

replaced resorption and ankylosis of left central incisor after dental traumatic injury. Autotransplantation of lower second premolar to the place of ankylotic central incisor was planned because orthodontic treatment plan involved extractions. Autotransplantation was performed in two stages because of soft tissues deficiency. Extraction of ankylotic 21 was done first with soft tissue reconstructing by remnants of dental sac. After soft tissue had healed and space had been opened 2 months after extraction, autotransplantation of 45 was done. Donor tooth was placed in the left maxillary central incisor region after drill of shaft with internal cooling according to measurements done on CBCT (+1mm for periapical tissues). Donor tooth was fixed with cross suture and 90° rotated to mimic cervical width of right central incisor. X- ray controls of autotransplanted tooth were done according to protocol of Andreassen et al. 1990. Continuing root formation without pathological changes were seen on x-rays. After the autotransplantation the tooth was freed of all occlusal contacts and orthodontic traction was applied 17 months after. Provisional build-up was done in the long axis of the root. The anatomic situation allowed non-prep composite build-up placement in relative dry field without silicone index. Bite plate was used to avoid articulation blocking after build-up. Teeth 14 and 45 were extracted 2 years after autotransplantation, because there were "saved" as spare donor teeth. Orthodontic treatment is continuing. Autotransplanted tooth development continues and is without complication. Up to date it is 4 years after autotransplantation.

Poster 20

„Jánošík" therapy – treatment of Class II with autotransplantation of extracted first upper premolars to the place of second lower premolars agenesis. 11 years follow-up.

MUDr. Ivana Dubovská Ph.D.[1], MUDr. Zdeněk Pokorný Ph.D.[1], MDDr. Barbora Vágnerová Ph.D.[1], MUDr. Wanda Urbanová Ph.D.[2]
[1]Institute of Dentistry and Oral Sciences, Faculty of Medicine and Dentistry, Palacký University, Olomouc, Czech Republic; [2]Department of Orthodontics and Cleft Anomalies, 3rd Medical Faculty, Charles University, Prague, Czech Republic

Treatment of Class II with extraction of first premolars is the first-choice method for autotransplantation of extracted first upper premolars to the place of second lower premolars agenesis [Zachrisson B.U. et al. 2004]. Case report shows 8 years old patient with class II. in both molars, agenesis of second lower premolars and lack of space for upper lateral incisors eruption. Serial extractions of 53,54,63,64 were performed to gain space for upper lateral incisors eruption and enhancing eruption of upper first premolars. Fully erupted upper first premolars were used as donors for autotransplantation to replace agenetic lower second premolars at the age of 9. Transpalatal bar was used for molars anchorage and his arm to avoid eruption of 25 and its occlusal contact with autotransplanted tooth, because of premature loss of 65 with large caries leason. 1 year after autotransplantation after spontaneous elimination of 55 and eruption of 15 transpalatal bar was removed. Start of fixed appliance treatment was performed after full eruption of all permanent teeth including second molars at 14 years of age (5 years after autotransplantation) because deep bite treatment demand. Autotransplanted tooth were x-ray evaluated according to protocol [Andreassen J.O. 1990]. Further root development of autotransplanted tooth, without periapical changes, with pulp obliteration can be seen on x-rays. Orthodontic treatment continues up to date.

Poster 21

Case report: Maxillary lateral incisor agenesis. Recipient site preparation using osseodensification burs.

Michal Štefanatný[1,2], Peter Dírer[1,3], Anna Macurová[1]
[1]Blanc Dental Studio, Zilina, Slovakia; [2]Department of Periodontology, UH Olomouc, Czech republic; [3]Department of Orthodontics, UH Olomouc, Czech republic

Aims: The aim of this case report is to discribe the effect of osseodensification burs in the preparation of the recipient site before autotransplantation.

Subject and Method: An 39-year old man with missing maxillary right lateral incisor, which was treated by using metal ceramic crown on tooth 13 and cantilever at the place of missing 12, about 6 years ago. The patient is suffering from low space for teeth 35 and 45 and missing teeth 12 and 37. Because of severe crowding in the lower jaw and one side missing lateral incisor, as a treatment plan, it was decided to reconstruct the missing tooth with autotransplantation of lower incisor instead of prosthodontic solution with implant or bridge.

Treatment: Therapy started with root canal treatment on tooth 32. Transplantation of this tooth to the position 12 was realized 4 weeks after RCT. Osseodensification burs (DensahTM) for recipient site preparation were used to preserve vestibular bone and achieve better primary stability of the transplanted tooth. Treatment with aligners started 4 weeks after transplantation. Provisonal crown on tooth 13 and provisonal composite veneer on tooth 12 were placed in another 10 weeks to improve smile aesthetics. Lithium-disilicate reconstructions are planned after orthodontic treatment.

Conclusion: In the compromised sites, especially in frontal maxila, we are able to preserve buccal bone when preparing recipient bed for transplanted tooth. Moreover, better primary stability could be achieved and there is no need to splint with neigbouring teeth. Implantation is still possible in the worst case of complicasions.

Czech Convention Bureau
CzechTourism

Czech Convention Bureau



official representation of the Czech Republic

—

destination advisory

—

support for candidacies and congresses

—

cooperation with professional associations

czechconvention.com

Czech Republic
The Country For The Future

PARTNEŘI / PARTNERS

Zlatý partner / Gold partner

Dentamed

Bronzový partner / Bronze partner

PRODENTA specialista na techniku PLANMECA

Partneři / Partners

DentalMonitoring

PRAHA PRAGUE PRAGA PRAG

The congress is held with the financial support of the capital Prague

Mediální partneři / Media partners

ORTODONCIE

Czech Convention Bureau CzechTourism

Vystavovatelé / Exhibitors

Dentamed (ČR), spol. s r.o.
Dental Monitoring SAS
PRODENTA s.r.o.
ITALDENT s.r.o.
Resorba s.r.o.
LASAK s.r.o.
Straumann s.r.o.

Beldental s.r.o.
Profitime s.r.o.
Curaden Czech, s.r.o.
Spofa Dental a.s.
Dentsply Sirona Poland Sp.Z.o.
W&H Dentalwerk Bürmoos GmbH
Just Dent s.r.o.

PROFIMED s.r.o.
JPS s.r.o.
Quintessenz Prag
4P&P, spol. s r.o.
Altis Group spol. s r.o.

VÝSTAVA / EXHIBITION

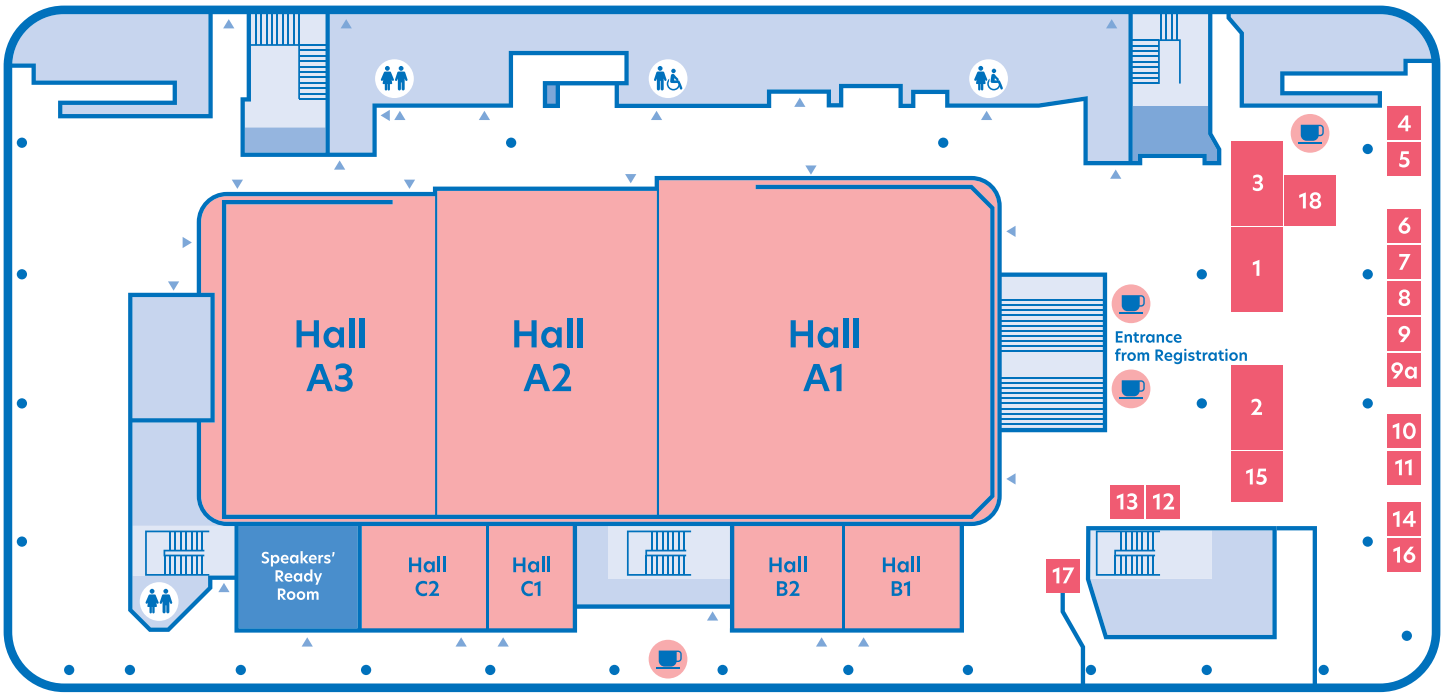

Vystavovatelé / Exhibitors

1	Dentamed (ČR), spol. s r.o.
2	Dental Monitoring SAS
3	PRODENTA s.r.o.
4	ITALDENT s.r.o.
5	Resorba s.r.o.
6	LASAK s.r.o.
7	Straumann s.r.o.
8	Beldental s.r.o.
9	Profitime s.r.o.
9a	Curaden Czech, s.r.o.
10	Spofa Dental a.s.
11	Dentsply Sirona Poland Sp.Z.o.
12	W&H Dentalwerk Bürmoos GmbH
13	Just Dent s.r.o.
14	PROFIMED s.r.o.
15	JPS s.r.o.
16	Quintessenz Prag
17	4P&P, spol. s r.o.
18	Altis Group spol. s r.o.

OBECNÉ INFORMACE

Registrace
Do prostoru přednáškového sálu v době odborného programu mají přístup pouze registrovaní účastníci. Do ostatních prostor a na slavnostní zahájení je vstup umožněn všem registrovaným včetně doprovodu.

Registrace předem přihlášených i nových účastníků probíhá ve foyer v přízemí Cubex Centra. Při registraci si zkontrolujte, zda jsou Vaše konferenční materiály kompletní, na pozdější reklamace nebude brán zřetel.

Registrace, pokladna, informace

Čtvrtek 19. května	08:00–17:00
Pátek 20. května	08:00–17:30
Sobota 21. května	08:30–17:30

Jmenovky
Účastníci jsou povinni po celou dobu konání kongresu nosit jmenovku, kterou obdrží při registraci. V případě ztráty jmenovky bude za opětné vystavení účtován poplatek 100 Kč.

DELEGATE	**Kongresový kurz a kongres**
DELEGATE	**Kongres**
SPEAKER	
EXHIBITOR	
STAFF	

Certifikát o účasti
Certifikát o účasti obdrží účastníci na vyžádání elektronicky po ukončení kongresu.

Elektronická posterová sekce
Elektronické postery bude možnost zhlédnout ve foyer kongresových sálů. K dispozici budou dotykové kiosky.

Výstava
Výstava firem prodávajících stomatologické a ortodontické materiály probíhá ve foyer kongresových sálů.

Stravování
V ceně účastnického poplatku jsou zahrnuty obědy a občerstvení v čase kávových přestávek. Kávové přestávky budou podávány v prostorách výstavy.

Obědy budou vydávány v prostorách výstavy.

Doprava
Doprava do/z místa konání kongresu nebude zajištěna.

Internetové připojení
Ve všech prostorách Cubex Centra je možné využít bezdrátové připojení Wi-Fi.

Prezidentský večer
Prezidentský večer se bude konat v pátek 20. května od 20 hodin v Kaiserštejnském paláci, Malostranské náměstí 23/37, Praha 1

K poslechu a tanci bude hrát Originální Pražský Synkopický Orchestr.

GENERAL INFORMATION

Registration
Only registered participants will be admitted to the scientific section, exhibition, poster section and courses.

Registration of the pre-registered and new participants is located in the foyer on the ground floor of the Cubex Centre. Please check your congress materials upon presentation. Late claims cannot be accepted.

Registration, Cash, Information

Thursday, May 19	08:00–17:00
Friday, May 20	08:00–17:30
Saturday, May 21	08:30–17:30

Badges
Participants will receive a name badge. Everyone is requested to wear this badge during all congress activities. Cost of replacing a lost or mislaid badge: 4 EUR.

DELEGATE	**Congress Course and Congress**
DELEGATE	**Congress**
SPEAKER	
EXHIBITOR	
STAFF	

Certificate of Attendance
Participants will receive a certificate of attendance in electronic form upon request after the congress.

Electronic Posters Session
Touch kiosks are located in the congress hall foyer.

Exhibition Area
Exhibition take place on the congress hall foyer.

Refreshments
Complimentary coffee and tea are available in the exhibition area on the congress foyer. Lunches are provided in the exhibition area. Both are free of charge for registered participants of the congress.

Transport Service
Transport service to the congress venue will not be arranged.

Wi-Fi
Free Wi-Fi connection is available in the Cubex Centre.

President's Reception
President's Reception will take place in Kaiserštejnský Palace, Malostranské náměstí 23/37, Prague 1 on Friday, May 20 from 20:00.

The evening will be accompanied by the Original Prague Syncopated Orchestra.

Transportation will not be arranged.

MĚSTO PRAHA

Praha, jedno z nejkrásnějších měst Evropy bývá často nazývána srdcem Evropy, matkou měst, Prahou stověžatou. Rozkládá se na březích řeky Vltavy. Praha hlavni město České republiky s počtem 1,2 milionu obyvatel je zároveň největším městem České republiky.

Zmínky o raném osídlení na obou březích Vltavy pocházejí již z doby kamenné. Založením Pražského hradu v 9. století dynastii Přemyslovců byly položeny základy české státnosti. Pražský hrad se stal sídlem českých králů a později presidentů. Za panování císaře Karla IV. ve 14. století dosáhlo město ohromného kulturního a hospodářského rozmachu. Vrcholem teto doby je kromě stavby pozoruhodného Karlova mostu především založení a stavba university.

Za zmínku stojí také podivínský panovník Rudolf II. z dynastie Habsburků, který obohatil umělecké sbírky císařského dvora o mnoho skvostných děl a přivedl do Prahy řadu pozoruhodných umělců a učenců. Pro milovníky historických staveb je Praha skutečným rájem. Za pozornost stojí nejen již zmiňovaný Pražský hrad a Karlův most, ale i řada paláců na Malé Straně a Starém Městě. Staré Město se svými středověkými uličkami, s nádherným Staroměstským náměstím nabízí úžasný romantický zážitek především při večerním osvětlení. Součást Starého Města – Židovské město, je jednou z největších a nejcennějších sbírek židovské kultury v Evropě.

Střetáváním slovanské, německé a židovské kultury se Praha stala také jedinečným kulturním centrem vyhledávaným mnoha umělci. V Praze žil Franz Kafka, pobýval Rainer Maria Rilke, Max Brod, Jaroslav Hašek. Známými návštěvníky Prahy z řad umělců byla také řada hudebníků – Wolfgang Amadeus Mozart, který zde složil svou operu Don Giovanni, Bedřich Smetana, Antonín Dvořák, Petr Iljič Čajkovskij, Ludwig van Beethoven a řada dalších. Praha přitahovala také vědce – na Karlově universitě svého času přednášel i slavný fyzik Albert Einstein.

Dnešní Praha se stává moderní evropskou metropolí s nabídkou bohatého kulturního života i s mnoha komerčními příležitostmi. Město poskytuje všechny druhy vysoce kvalifikovaných služeb, nabízí řadu nejmodernějších nákupních center stejně jako nepřeberné množství malých obchůdků, zábavních center, pohostinských zařízení s tradičními českými hospodami servírujícími vynikající české pivo.

THE CITY OF PRAGUE

Prague, one of the most beautiful cities in Europe, is often mentioned as the Europe's heart, the Mother of the cities, the city of hundred towers. Prague being the biggest city of the Czech Republic with 1,2 mil. Inhabitants is also the capital of the country.

The first mentioning of the settlements along the both banks of the river Vltava goes back to the Stone Age. The dynasty of the Premyslovci has founded the Czech state by founding the Prague Castle in the 9th century. The Prague Castle has become the seat of the Bohemian Kings and later on of the Czech Presidents. The city has reached huge cultural and the economical development during the rule of the Emperor Charles IV in the 14th century. The foundation and the creation of the University was the peak of the epoque besides the construction of the picturesque Charles Bridge.

Also the eccentric King Rudolf II of the Habsburg dynasty is worth mentioning. He enriched the art collections of the emperor's court with many masterpieces and brought many famous artists and scientists to Prague. Prague is a real heaven for people who like historical architecture. Not only the Prague Castle and the Charles bridge are worth mentioning, but also several palaces in the Old Town and the Lesser Town. The Old Town with the medieval streets and the beautiful Old Town Square off ers the splendid experience, first of all under the nocturnal lights. The Jewish Town, the part of the Old Town hosts one of the biggest and the most precious collections of the Jewish culture in Europe.

The city where Slavic, German and Jewish culture meet together, Prague has become a unique cultural center beloved by many people of art and science. Franz Kafka lived in Prague, Rainer Maria Rilke, Max Brod, and Jaroslav Hašek stayed in the city. The well known visitors of Prague were famous musicians: Wolfang Amadeus Mozart, who composed the opera Don Giovanni, Bedřich Smetana, Antonin Dvořak, Petr Iljič Tchaikovsky, Ludwig van Beethoven and others. Prague also attracted scientists, the famous physicist Albert Einstein also lectured at the Prague University.

The Prague of today is becoming a modern European city with a great off er of the cultural life and many commercial opportunities. The city off ers all kind of high quality services, big modern shopping centres and small shops with traditional Czech gifts as crystal glass, Czech garnets, woodcraft, leisure time centers, pubs with traditional Czech cuisine and splendid Czech beer.

MAPA PRAHY / MAP OF PRAGUE

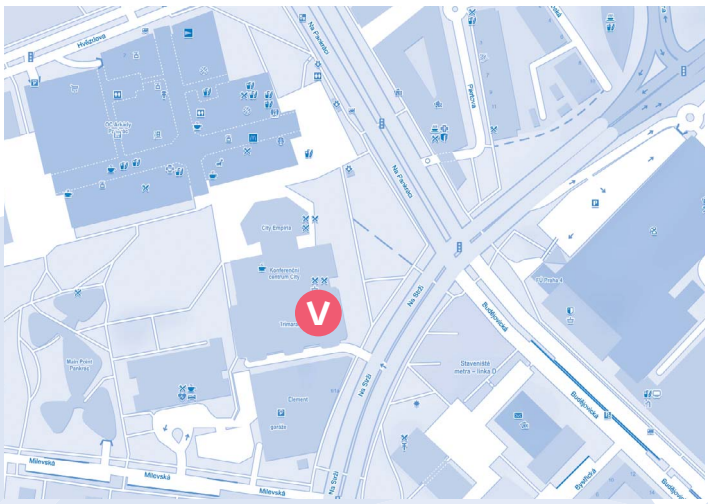

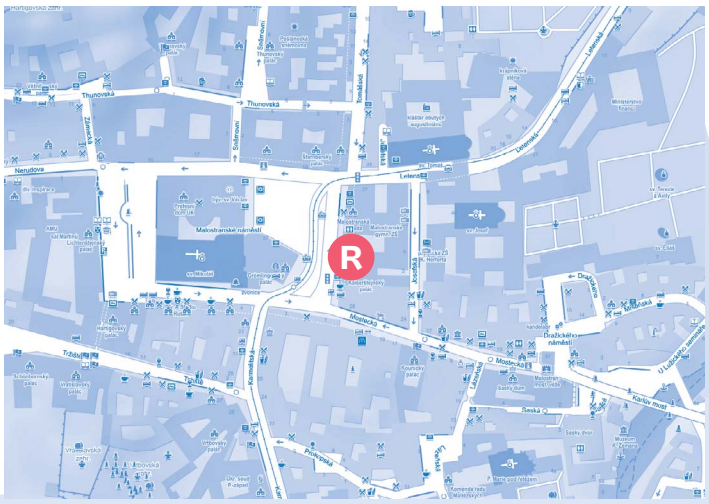

V **Místo konání / Congress Venue**
Cubex Centre Prague

R **Prezidentský večer / President's Reception**
Kaisterštejnský palác / Kaiserštejnský Palace

Doprava z místa konání kongresu /
How to get there from the congress venue:
Metro Line C
Pankrác ❶ → Muzeum ❷ **přestup na linku A / change to Line A**
Muzeum ❷ → Malostranská ❸
Tram ❸ 12, 20, 22, 32 to Malostranské náměstí ❹ (1 stop)

Monitoring na dálku

Monitorujte všechny své pacienty pomocí jednoho workflow pro úplnou kontrolu nad léčbou

DentalMonitoring
dental-monitoring.com

Zachovejte svůj přístup k plánování léčby. Pomáháme vám škálovat pomocí virtualizace a automatizace všech neklinických postupů.

- Kompletní přehled pro vyšší úroveň kontroly během celého ošetření
- Sledujte všechny své pacienty s ortodontickou léčbou v rámci jednoho pracovního postupu
- Zlepšení komunikace mezi ošetřujícím týmem a pacienty

Pro více informací kontaktujte:
Radim Mikeš, tel.: +420 776 475 422, e-mail: r.mikes@dental-monitoring.com
Martin Polák, tel.: +420 778 514 606, e-mail: m.polak@dental-monitoring.com

Planmeca Compact i5

Funkční, praktická a krásná

Nepřekonatelná ergonomie a design.

Uvolněný pacient = pohodlné vyšetření.

Ochrana před infekcí je nejvyšší prioritou.

CZ: +420605756950 | SK: +421910302329
www.prodenta.cz | www.prodenta.sk
info@prodenta.cz | info@prodenta.sk
Prodenta CZ/SK

PRODENTA
specialista na techniku
PLANMECA

Dentamed

Domluvte si s námi individuální podmínky

Kateřina Vostárková
manažer pro klíčové zákazníky

+420 777 631 973
katerina.vostarkova@dentamed.cz
dentamed.cz

Největší sklad spotřebního materiálu s dodáním do 24 hodin k dispozici na **eshop.dentamed.cz**